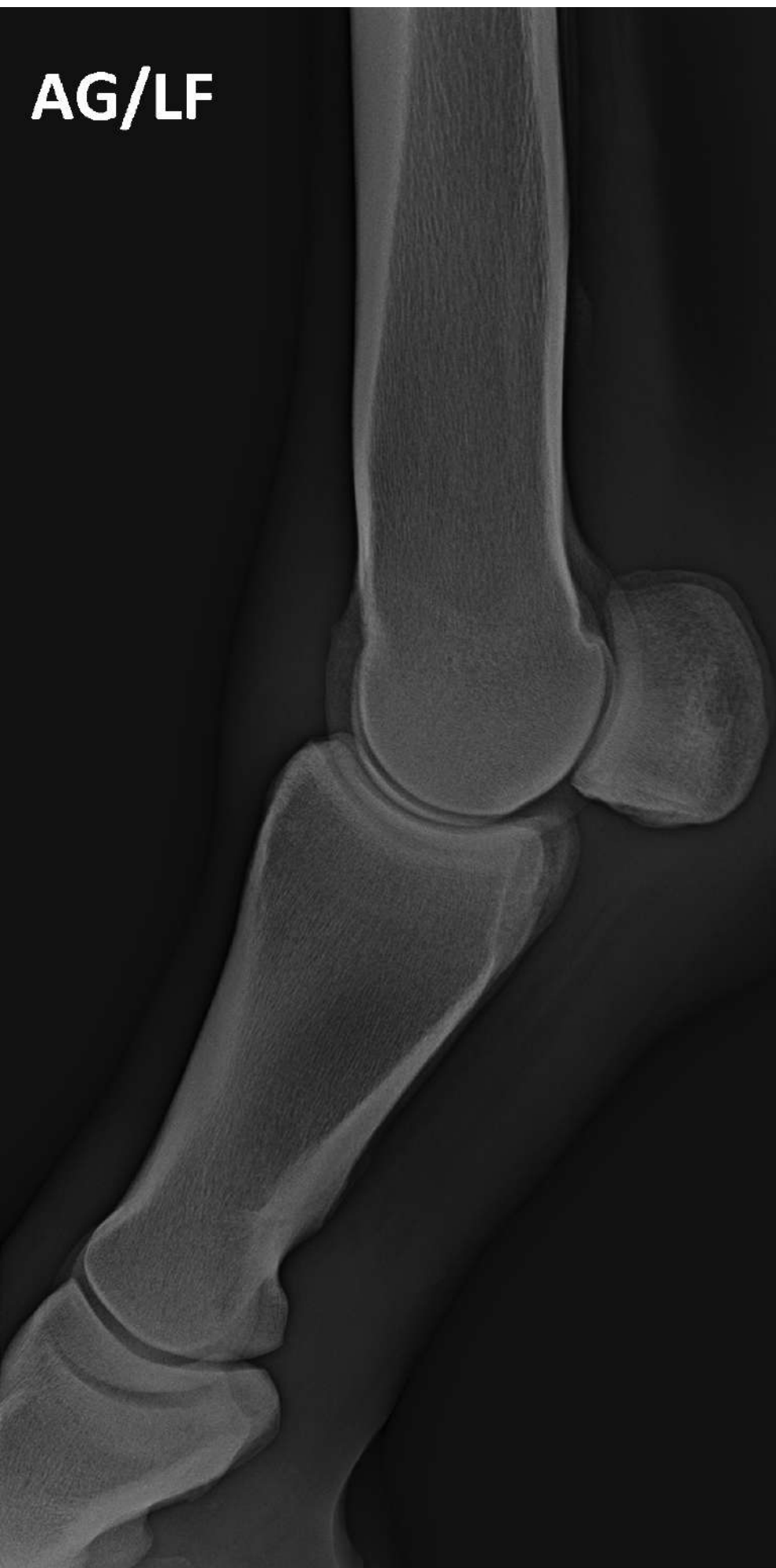
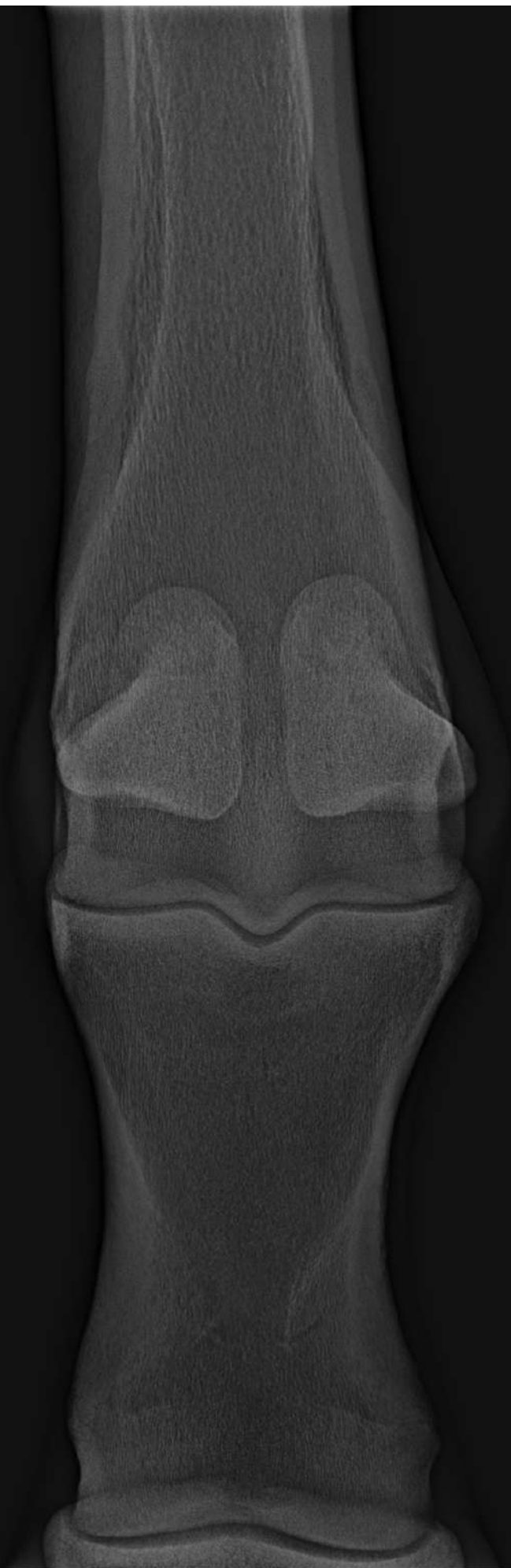
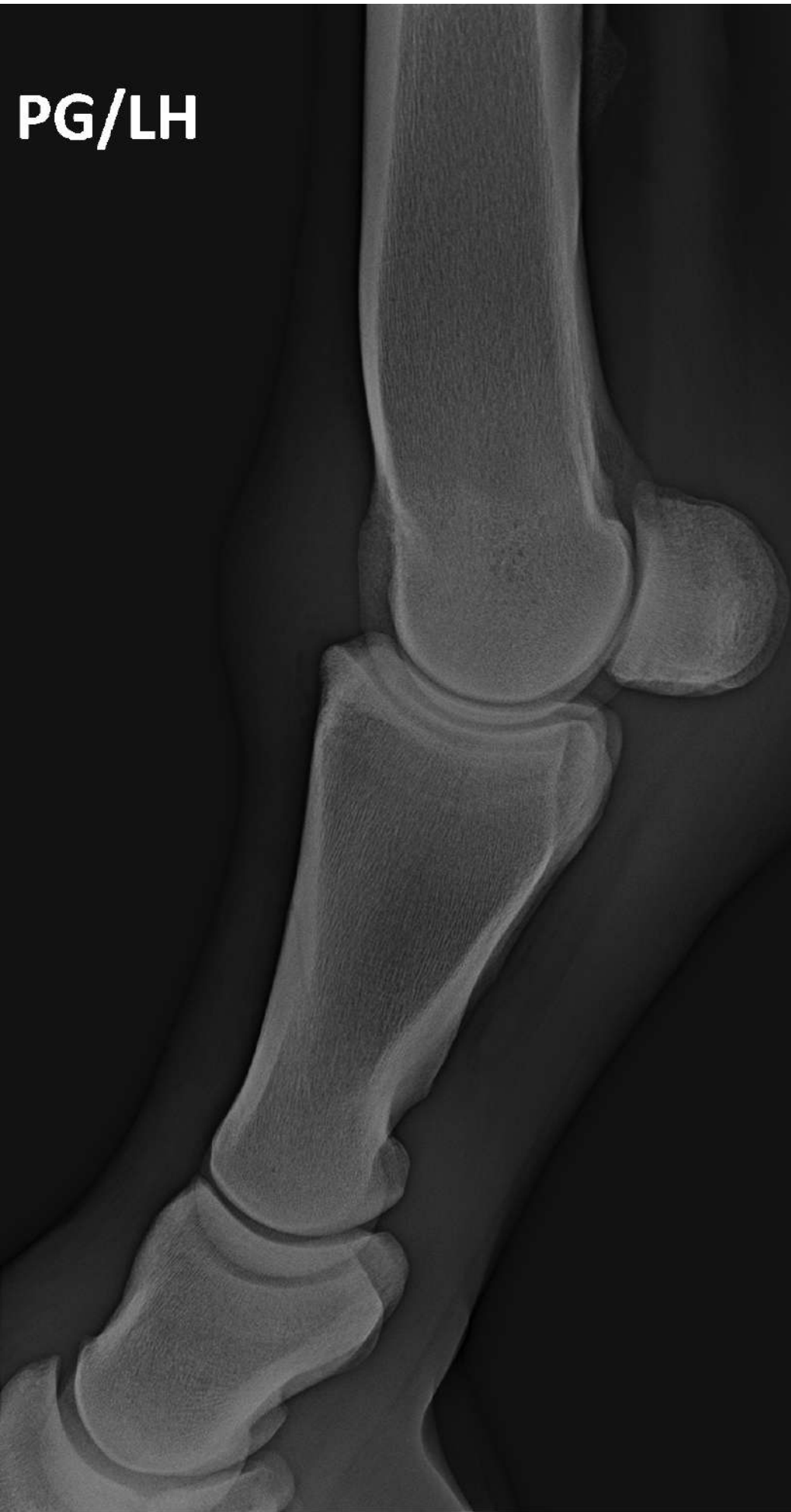AG/LF

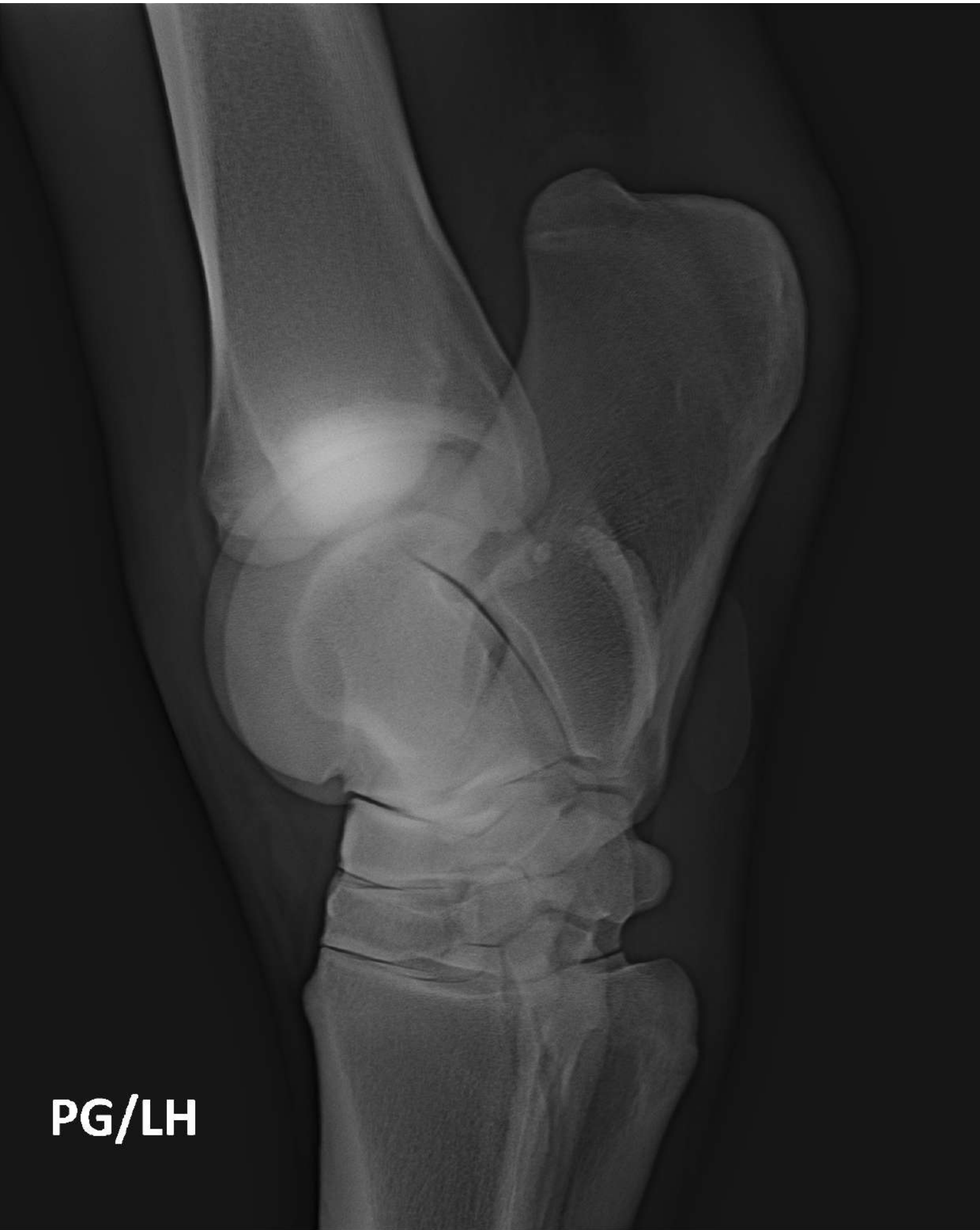

AG/LF



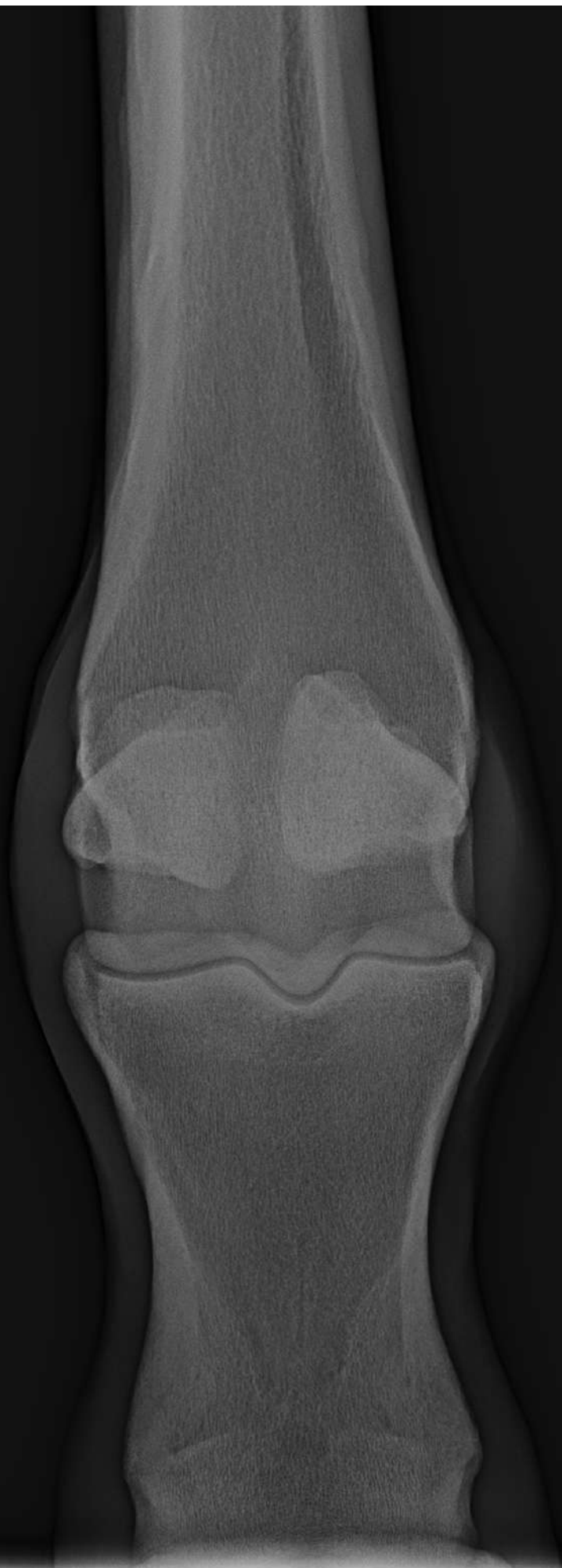PG/LH





PG/LH

PG/LH

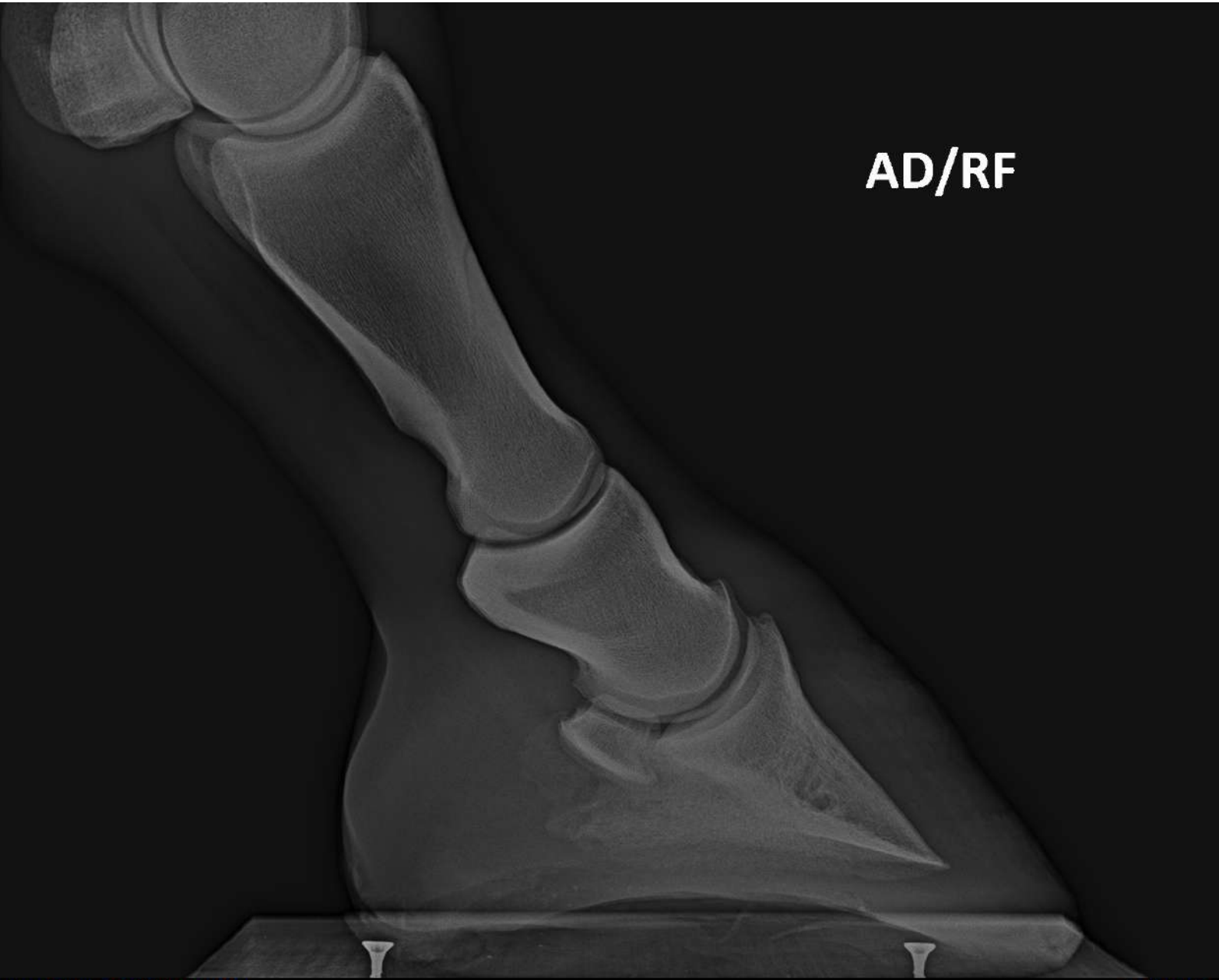




PG/LH



PG/LH



AD/RF

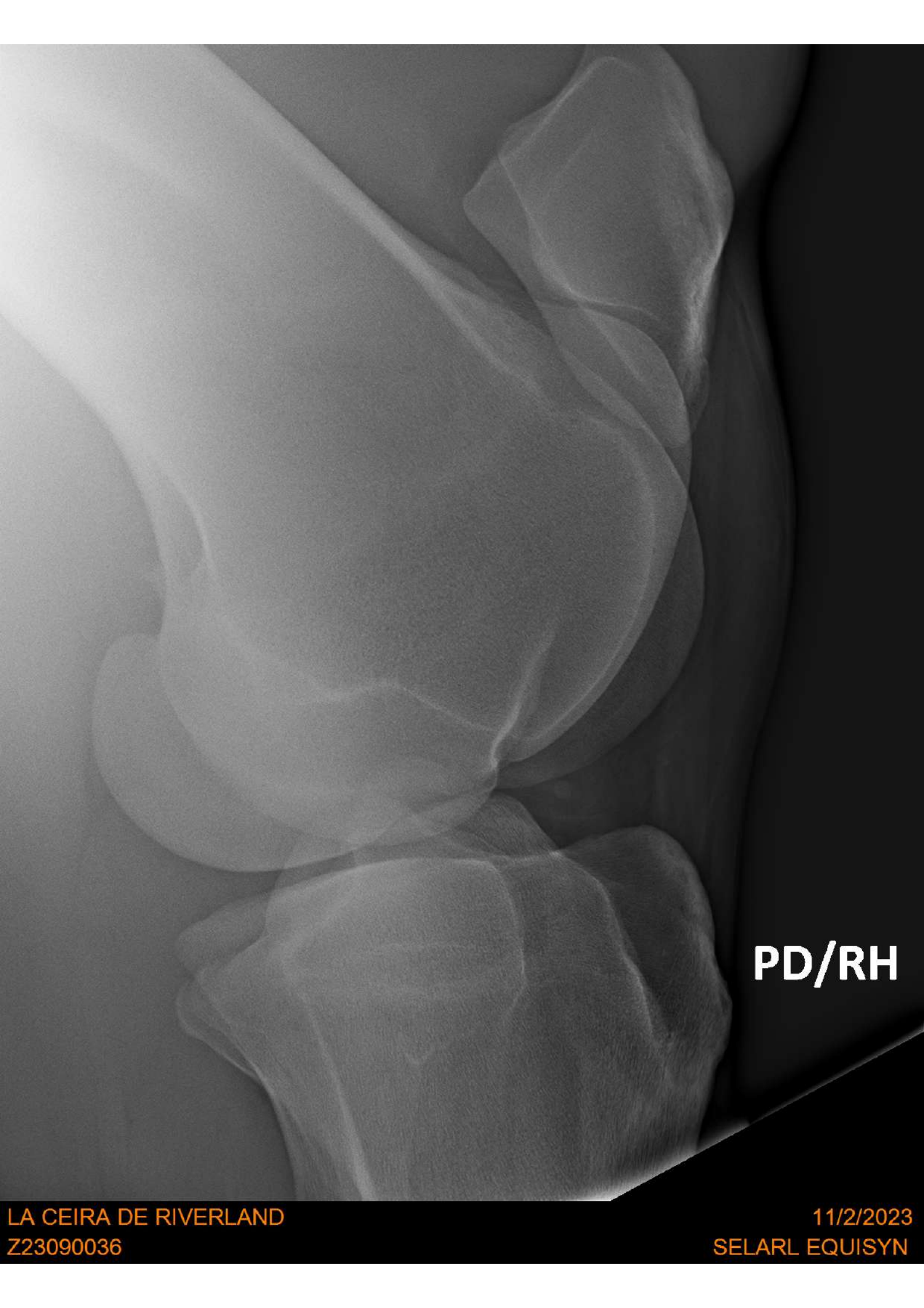
PG/LH



PD/RH

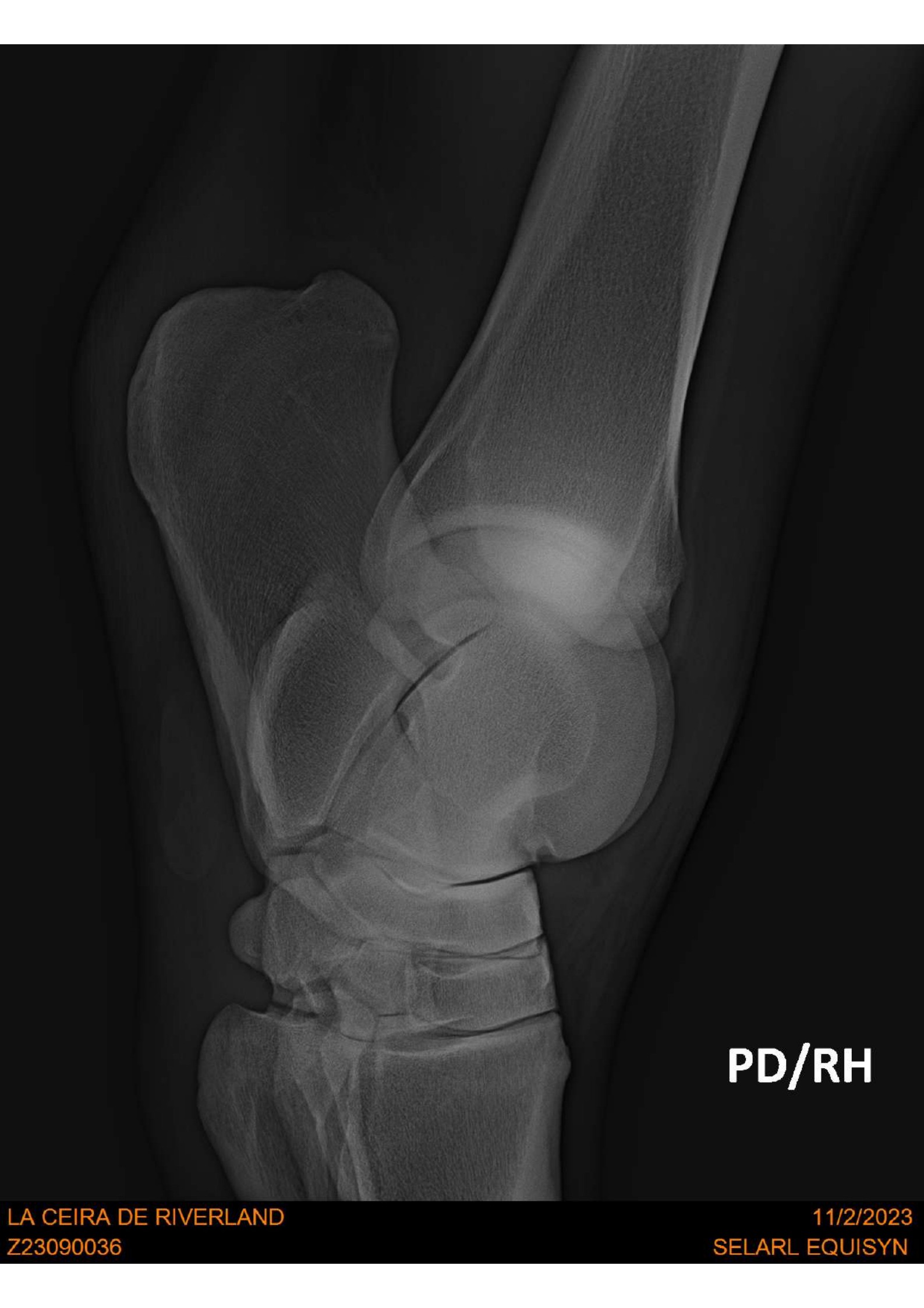LA CEIRA DE RIVERLAND
Z23090036

11/2/2023
SELARL EQUISYN



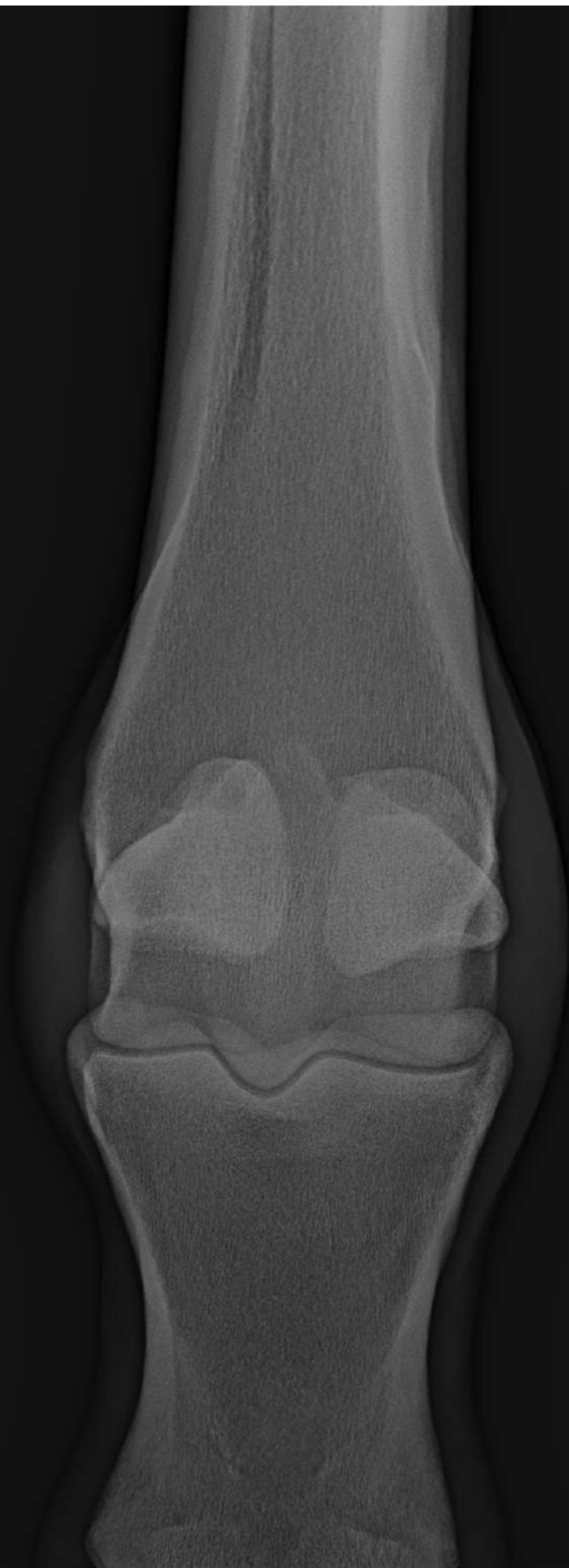PD/RH

PD/RH

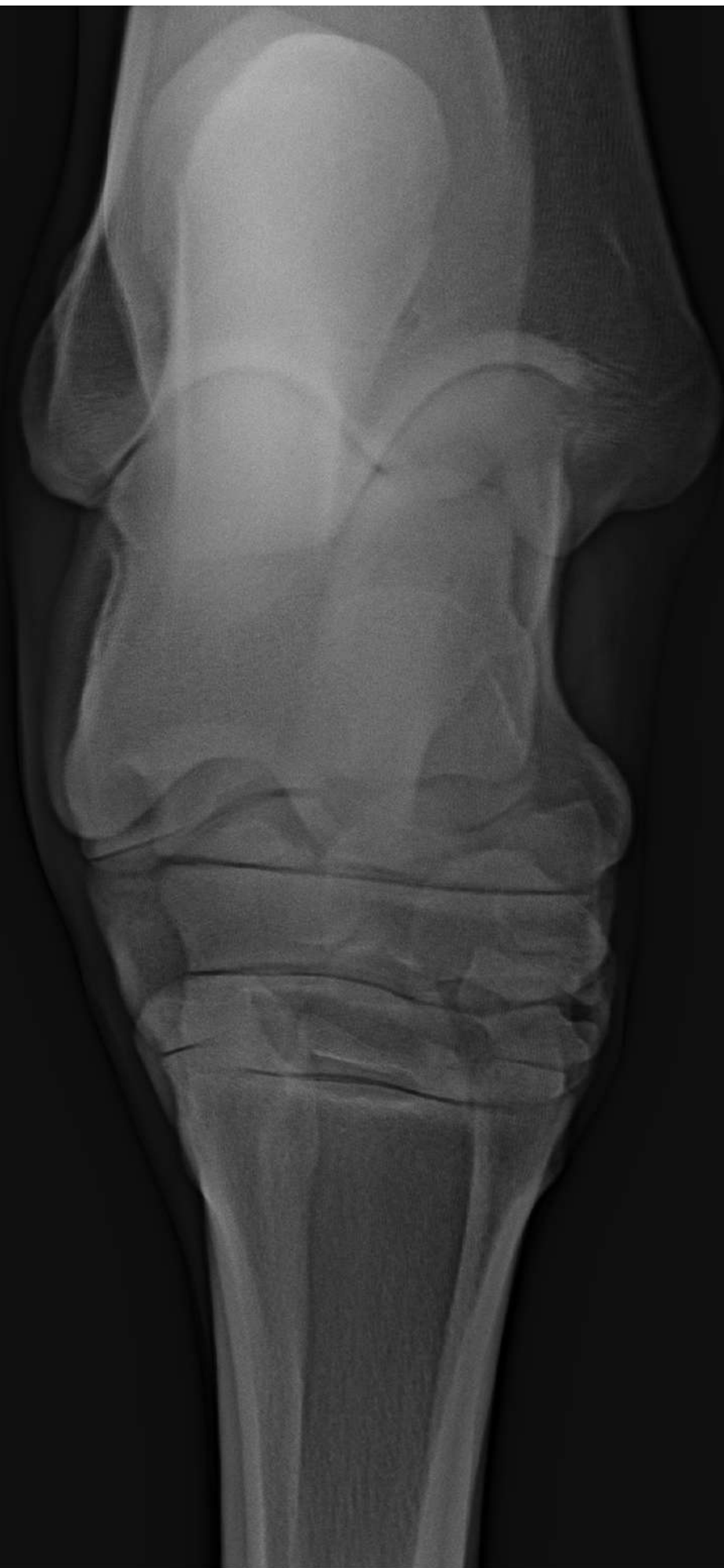

PD/RH

PD/RH

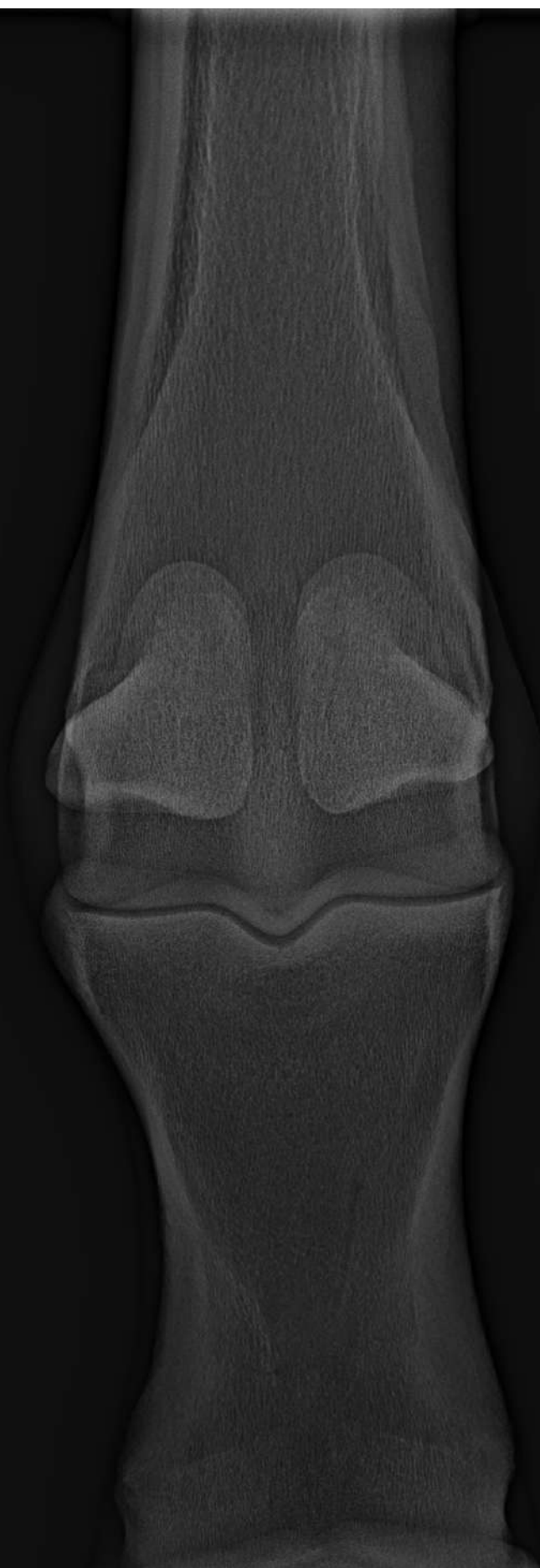

PD/RH



AD/RF

AD/RF





AG/LF

This is an anteroposterior (AP) radiograph of a horse's lumbar vertebrae. The image shows the bony structures of the spine, including the vertebral bodies, intervertebral discs, and the sacrum. The vertebrae are arranged in a column, with the sacrum at the bottom. The intervertebral discs are visible between the vertebral bodies. The sacrum is a large, triangular bone at the base of the spine. The text 'AG/LF' is printed in the upper right corner of the image.

AG/LF

LA CEIRA DE RIVERLAND
Z23090036

11/2/2023
SELARL EQUISYN

AD/RF