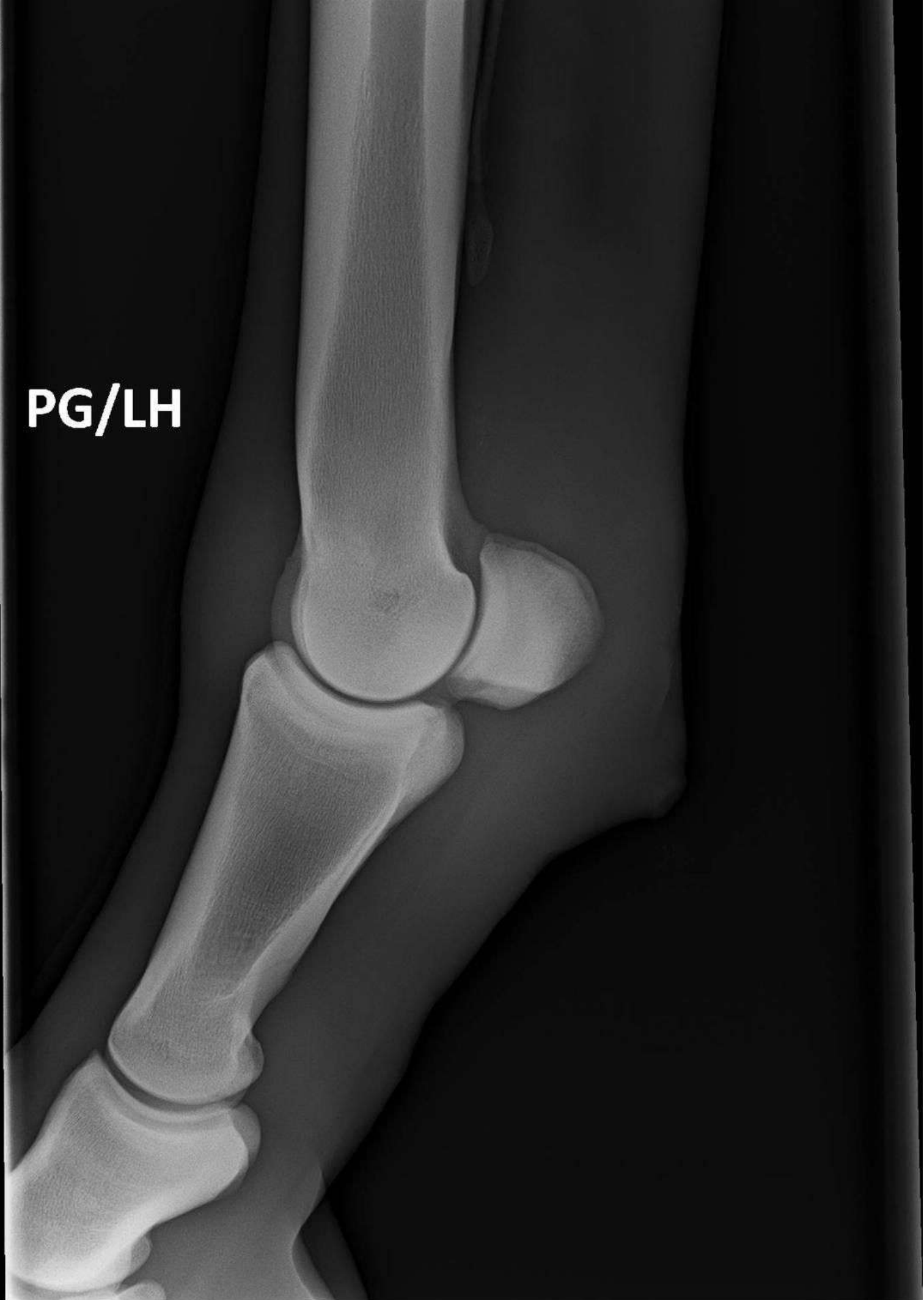


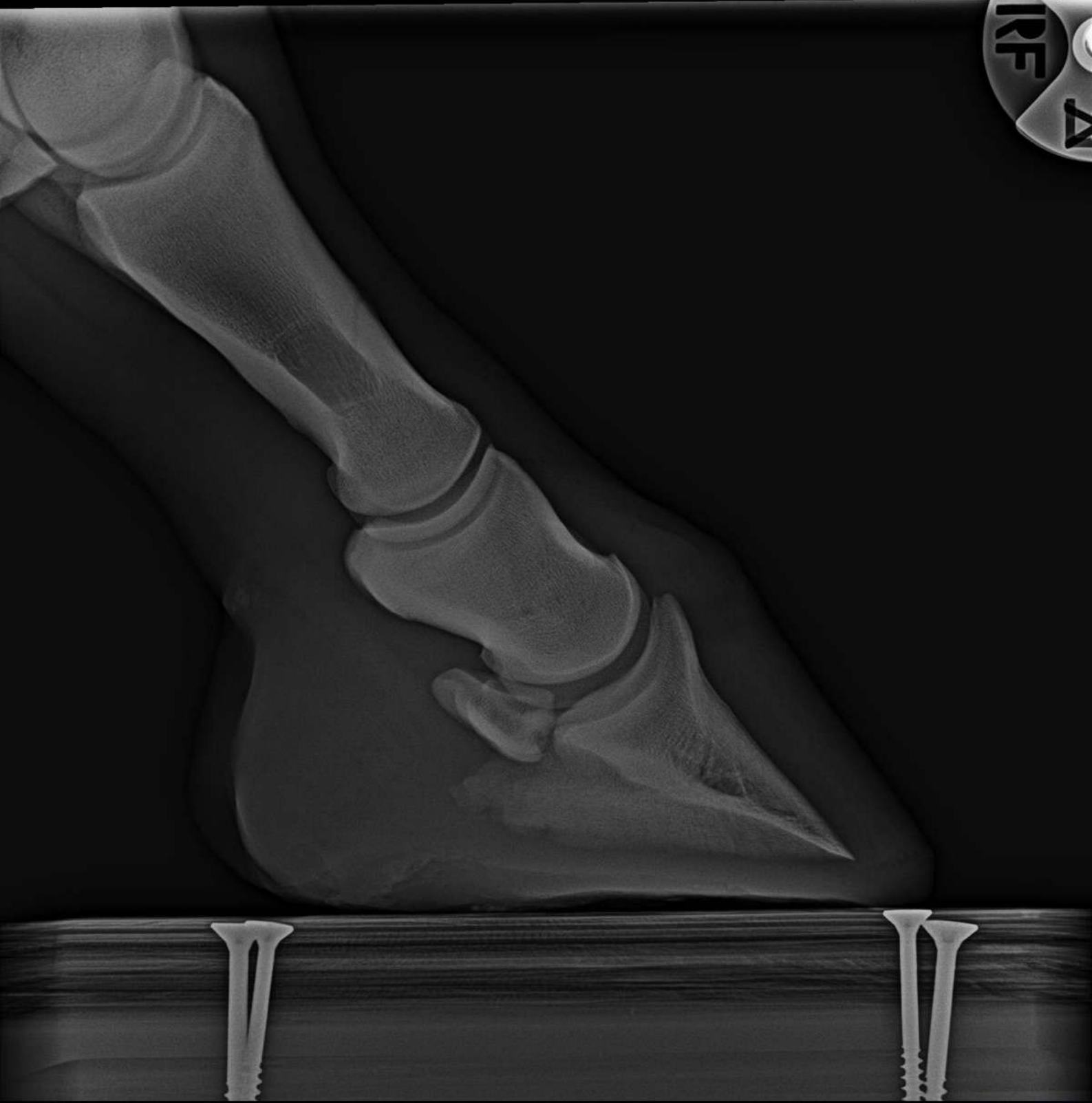
PG/LH

This is an anteroposterior (AP) radiograph of a knee joint. The image shows the distal femur at the top and the proximal tibia below it. A total knee replacement is visible, consisting of a femoral component on the distal femur and a tibial component on the proximal tibia. The femoral component has a rounded, dome-like shape, and the tibial component has a matching concave surface. The joint space is well-defined, and there is no obvious evidence of loosening or fracture. The surrounding soft tissue and bone structure appear normal for a post-operative knee.

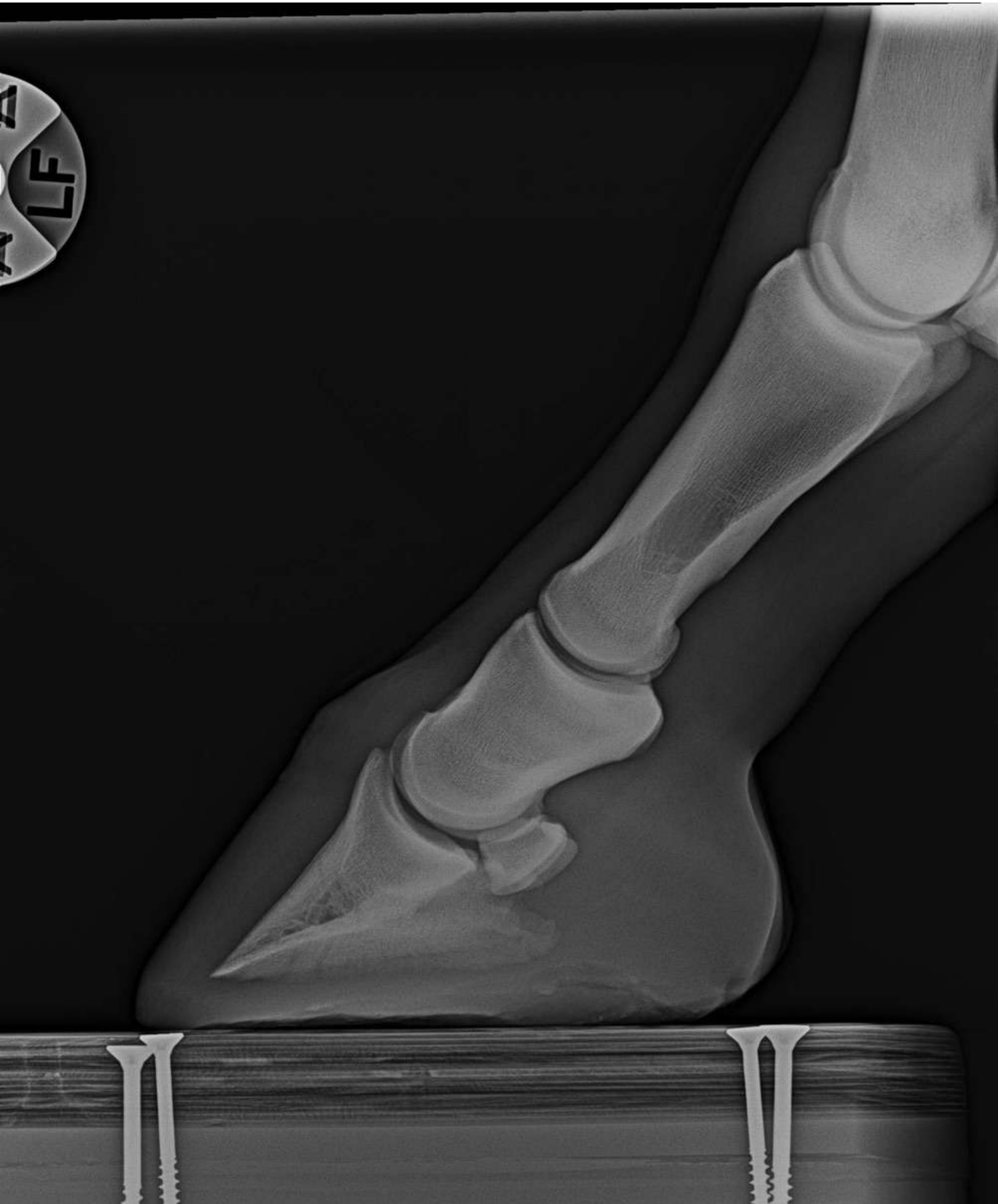PG/LH





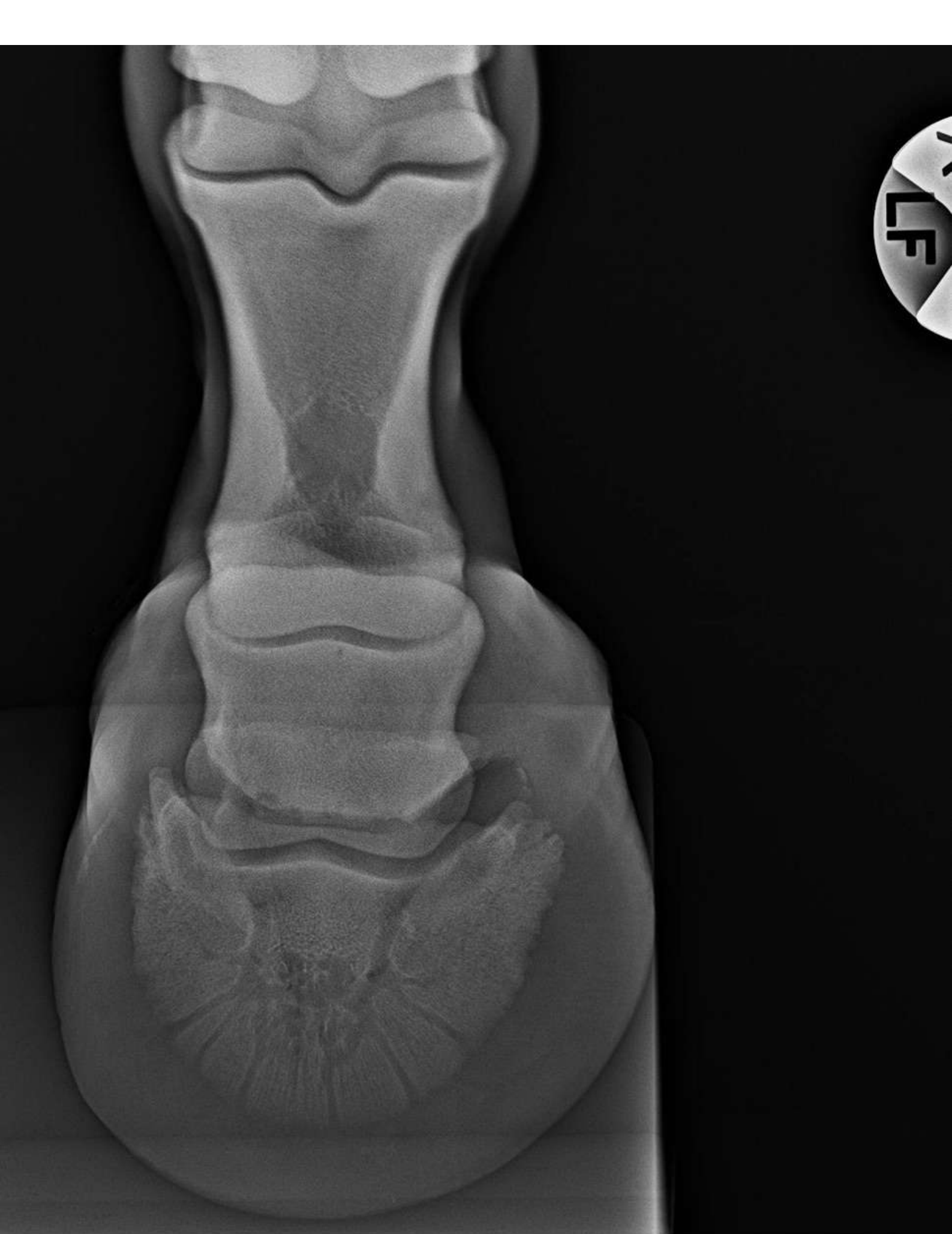LAURA DE SIJU==
CU00000195

09/10/2023
La Clinique du Cheval



LAURA DE SIJU==
CU00000195

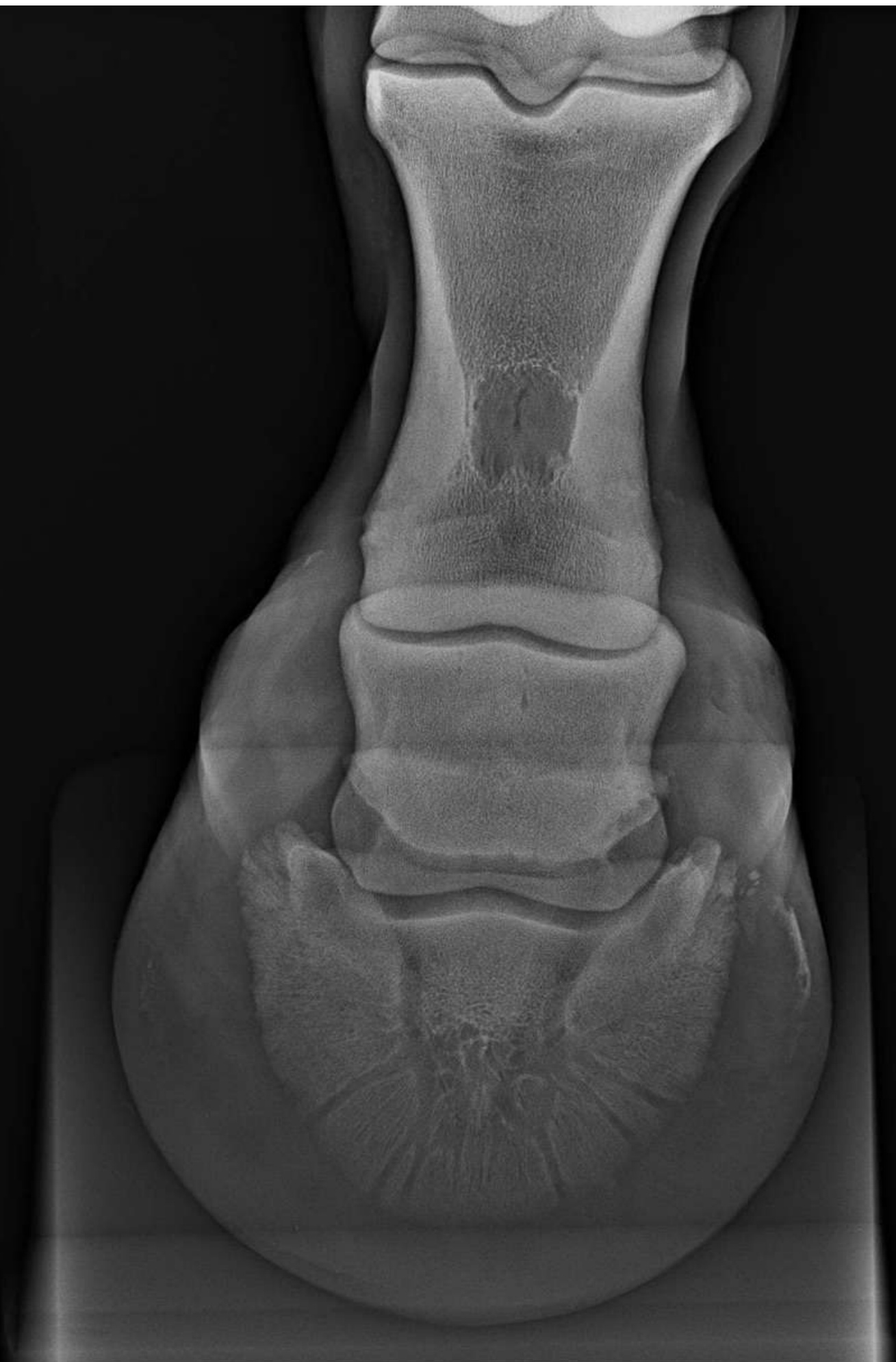09/10/2023
La Clinique du Cheval



LAURA DE SIJU==
CU00000195

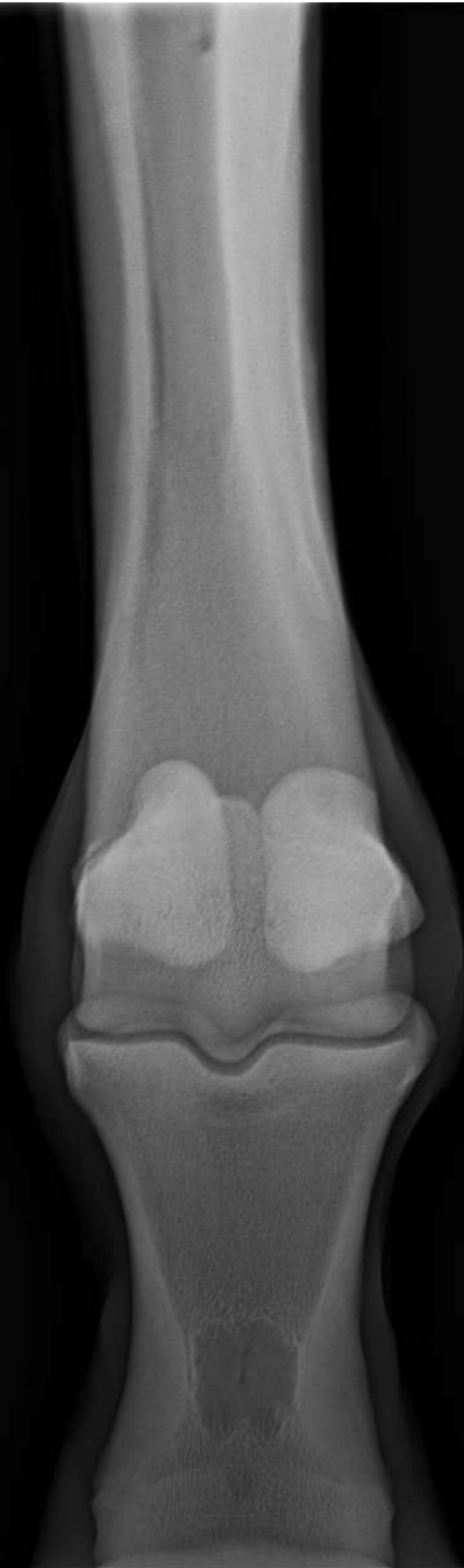09/10/2023
La Clinique du Cheval

RF



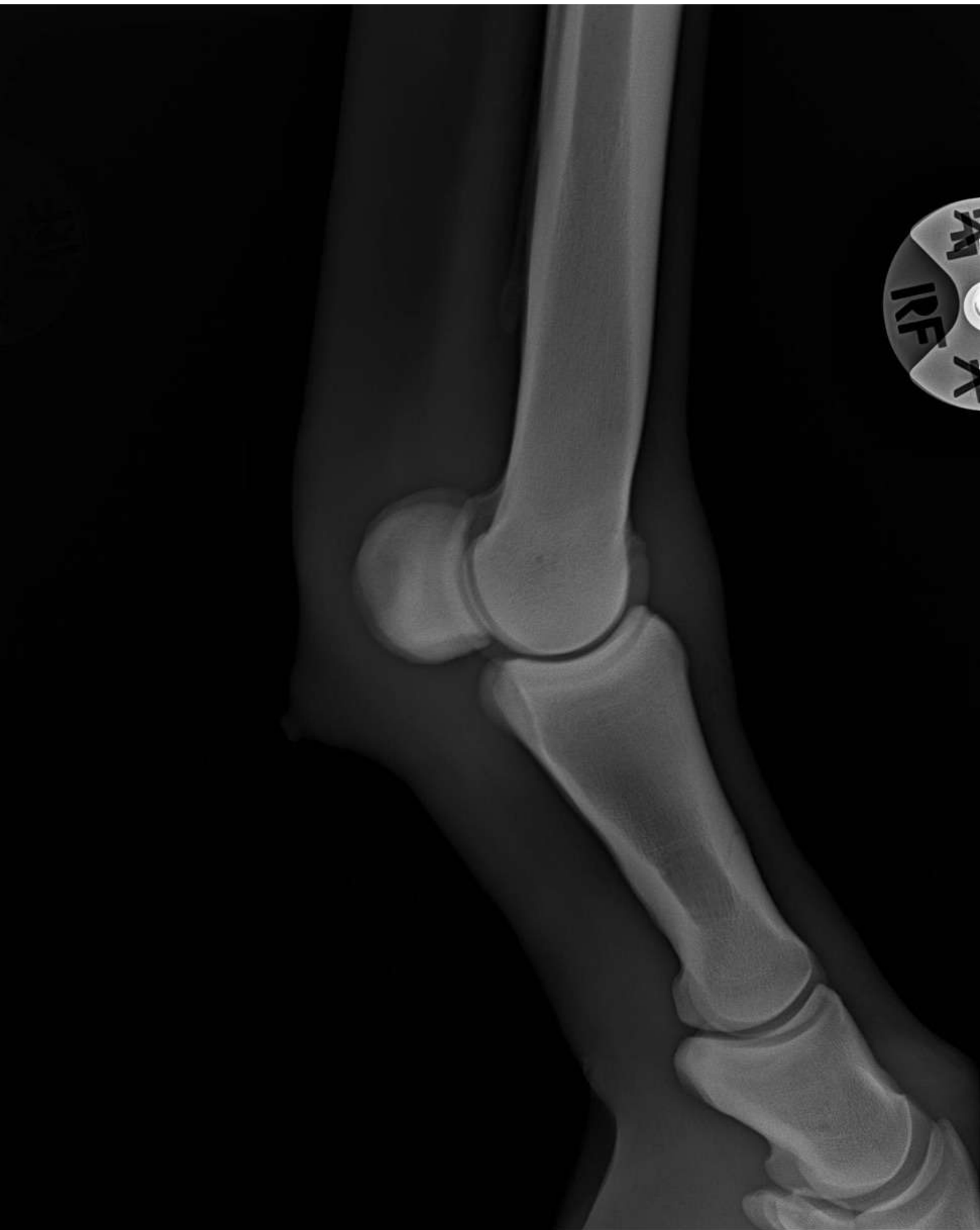LAURA DE SIJU==
CU00000195

09/10/2023
La Clinique du Cheval



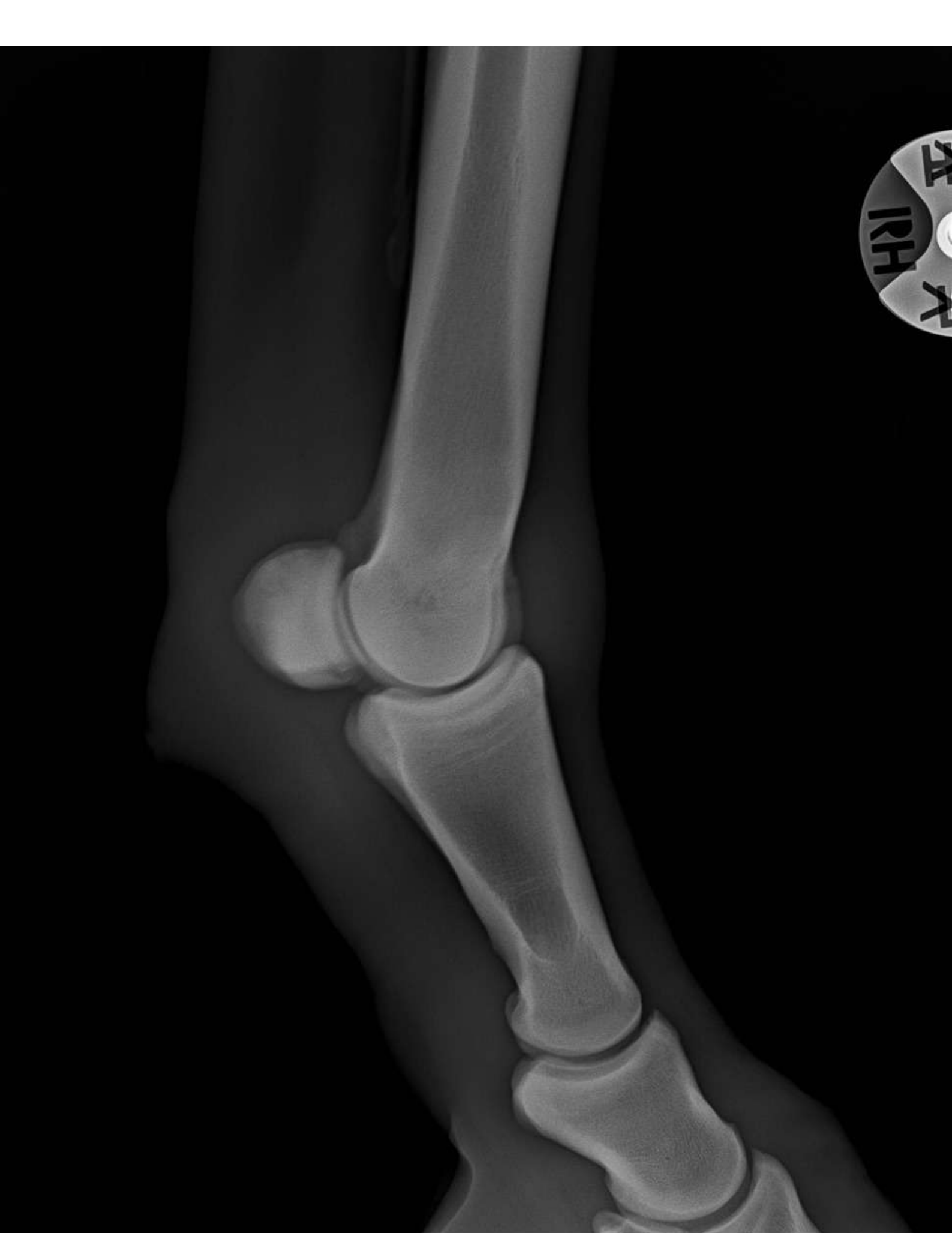LAURA DE SIJU==
CU00000195

09/10/2023
La Clinique du Cheval



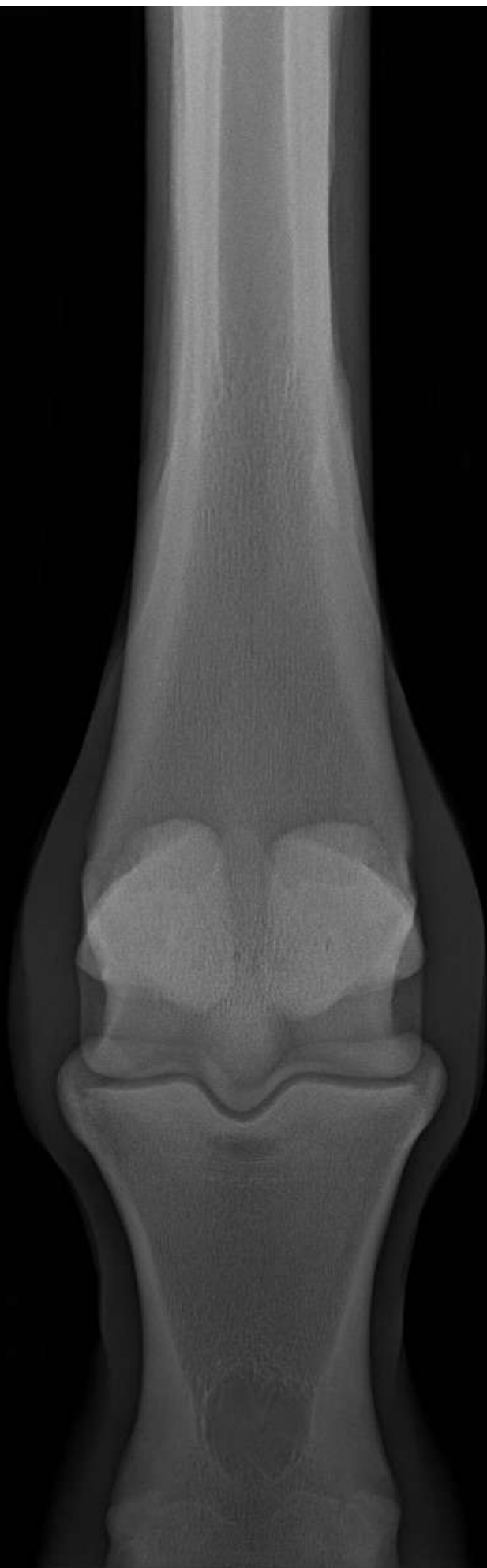LAURA DE SIJU==
CU00000195

09/10/2023
La Clinique du Cheval



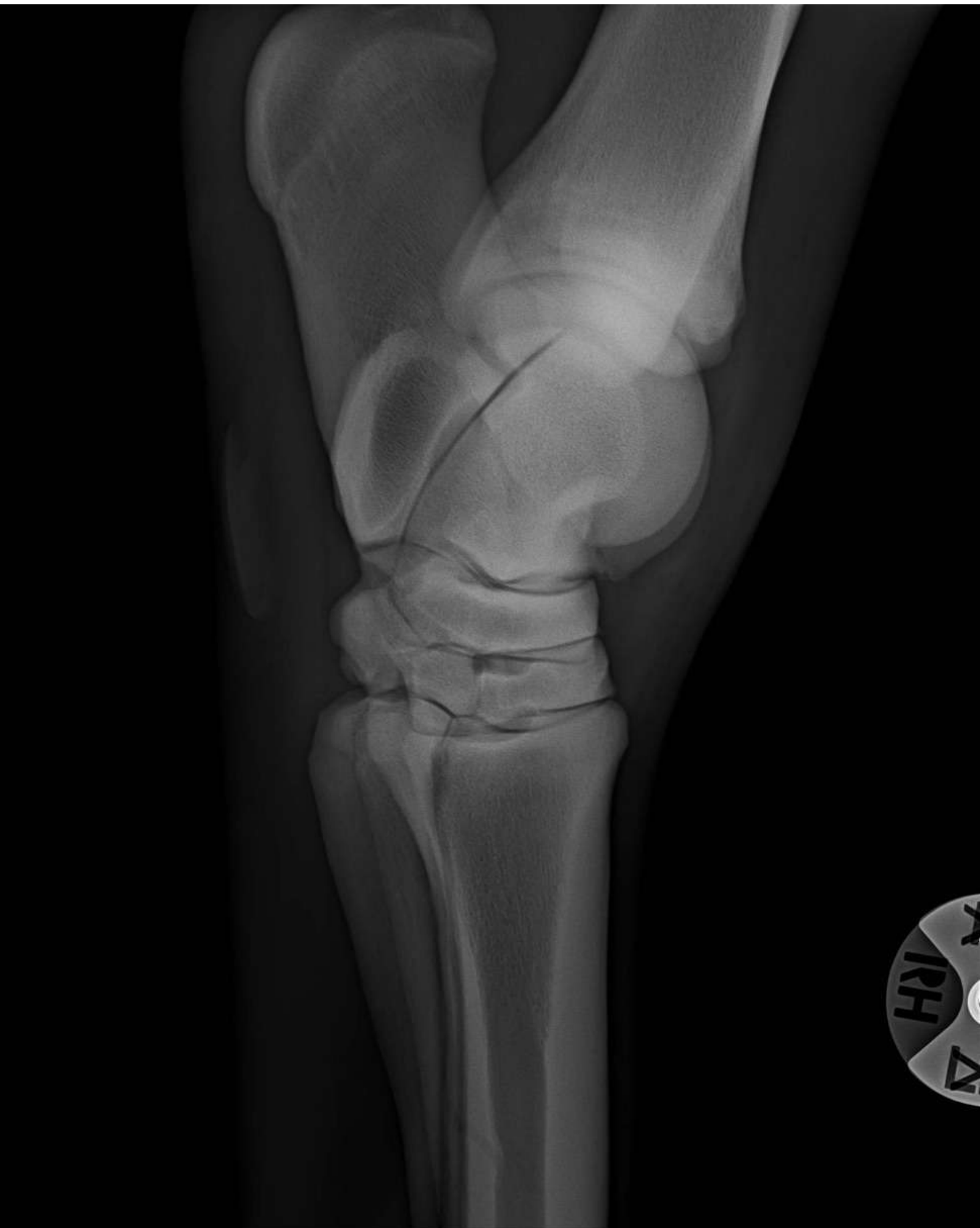LAURA DE SIJU==
CU00000195

09/10/2023
La Clinique du Cheval



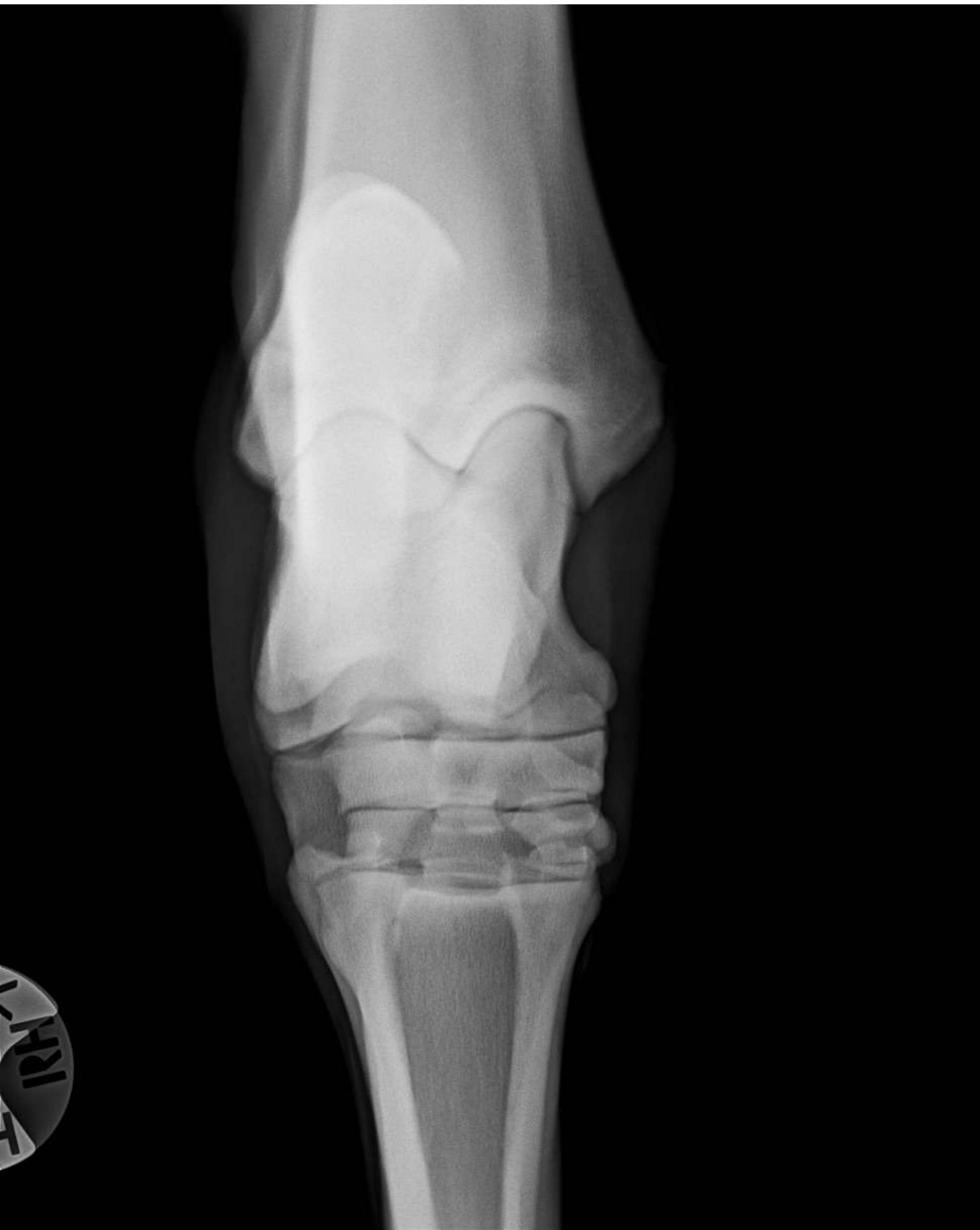LAURA DE SIJU==
CU00000195

09/10/2023
La Clinique du Cheval



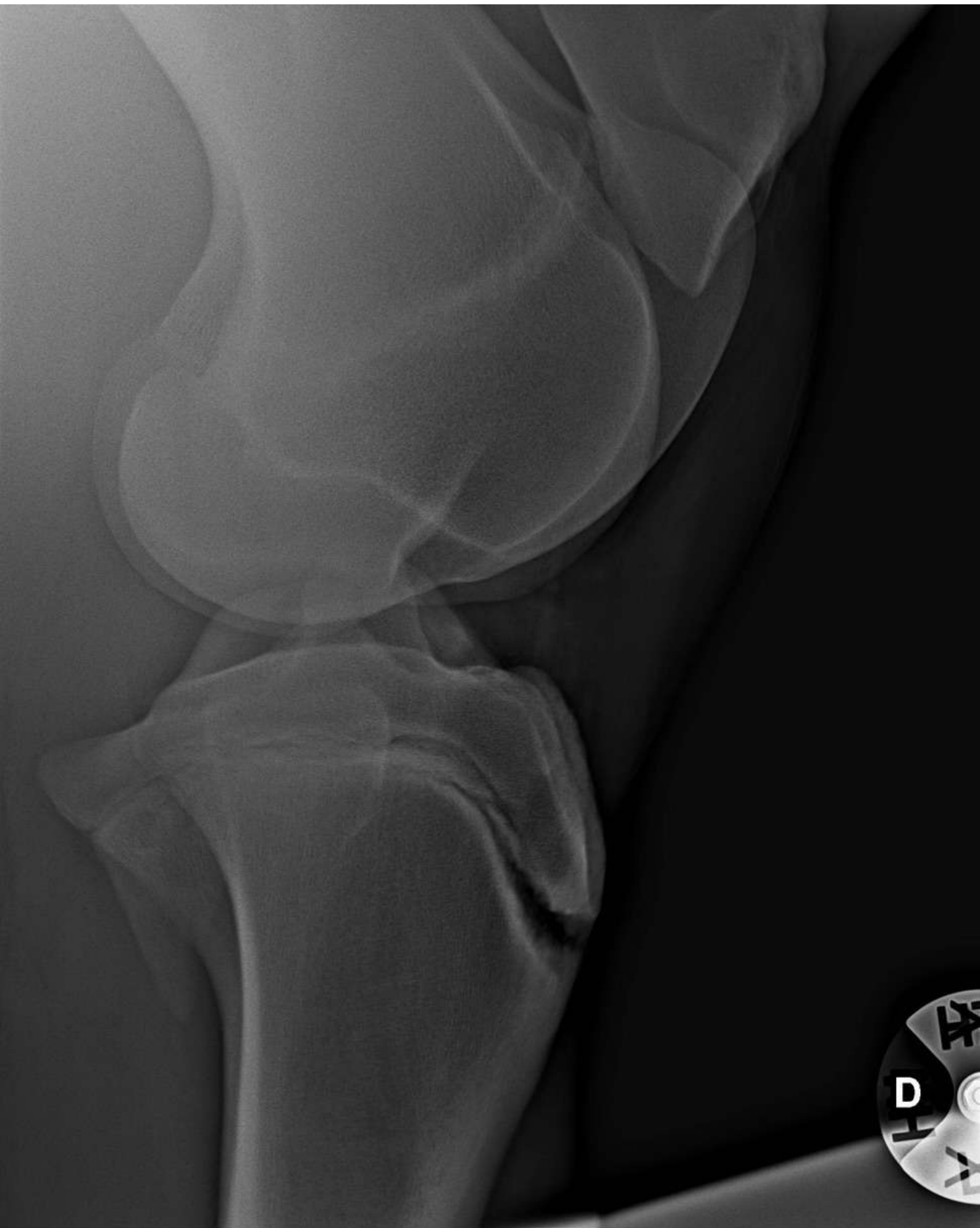LAURA DE SIJU==
CU00000195

09/10/2023
La Clinique du Cheval



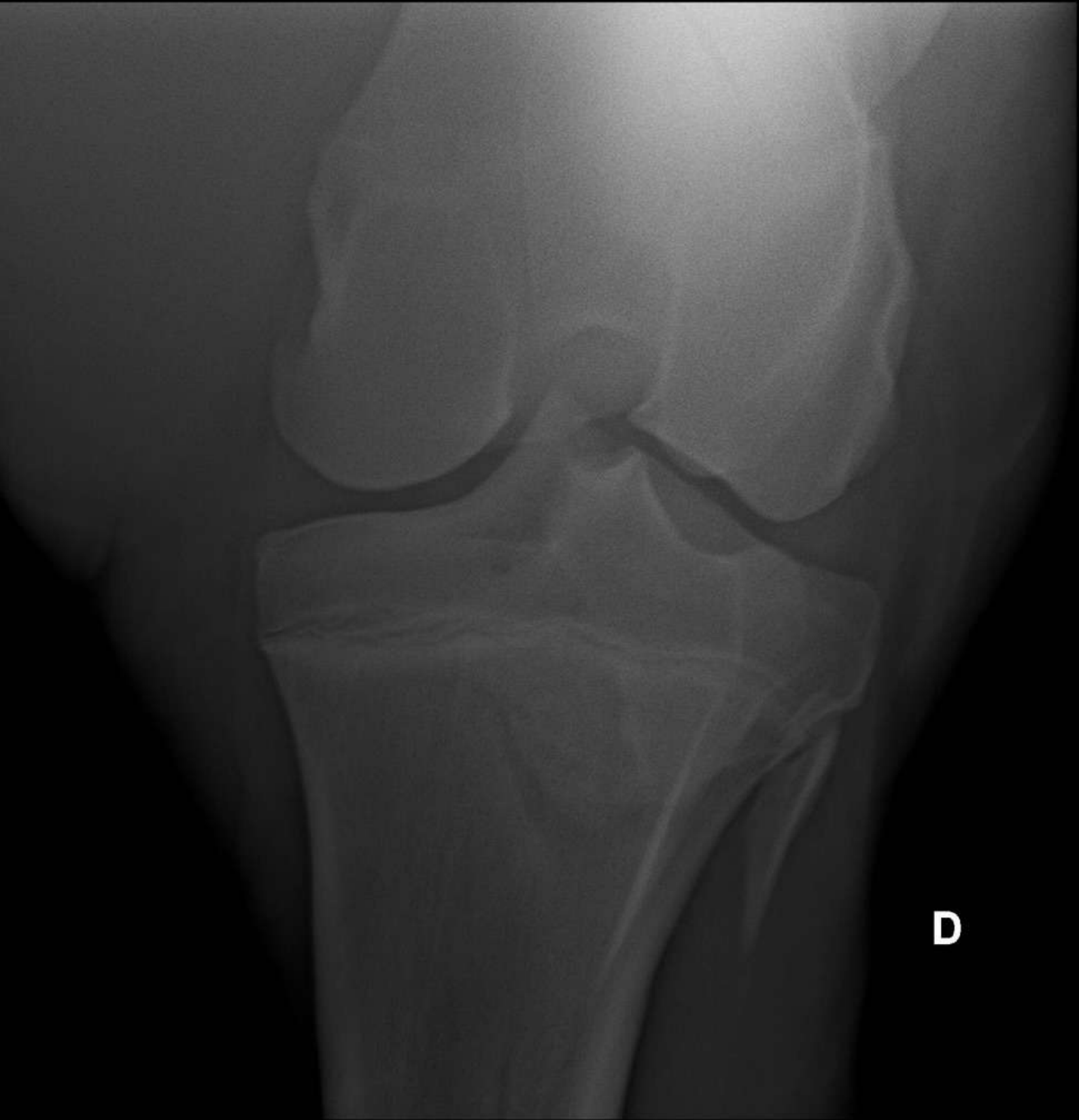
LAURA DE SIJU==
CU00000195

09/10/2023
La Clinique du Cheval

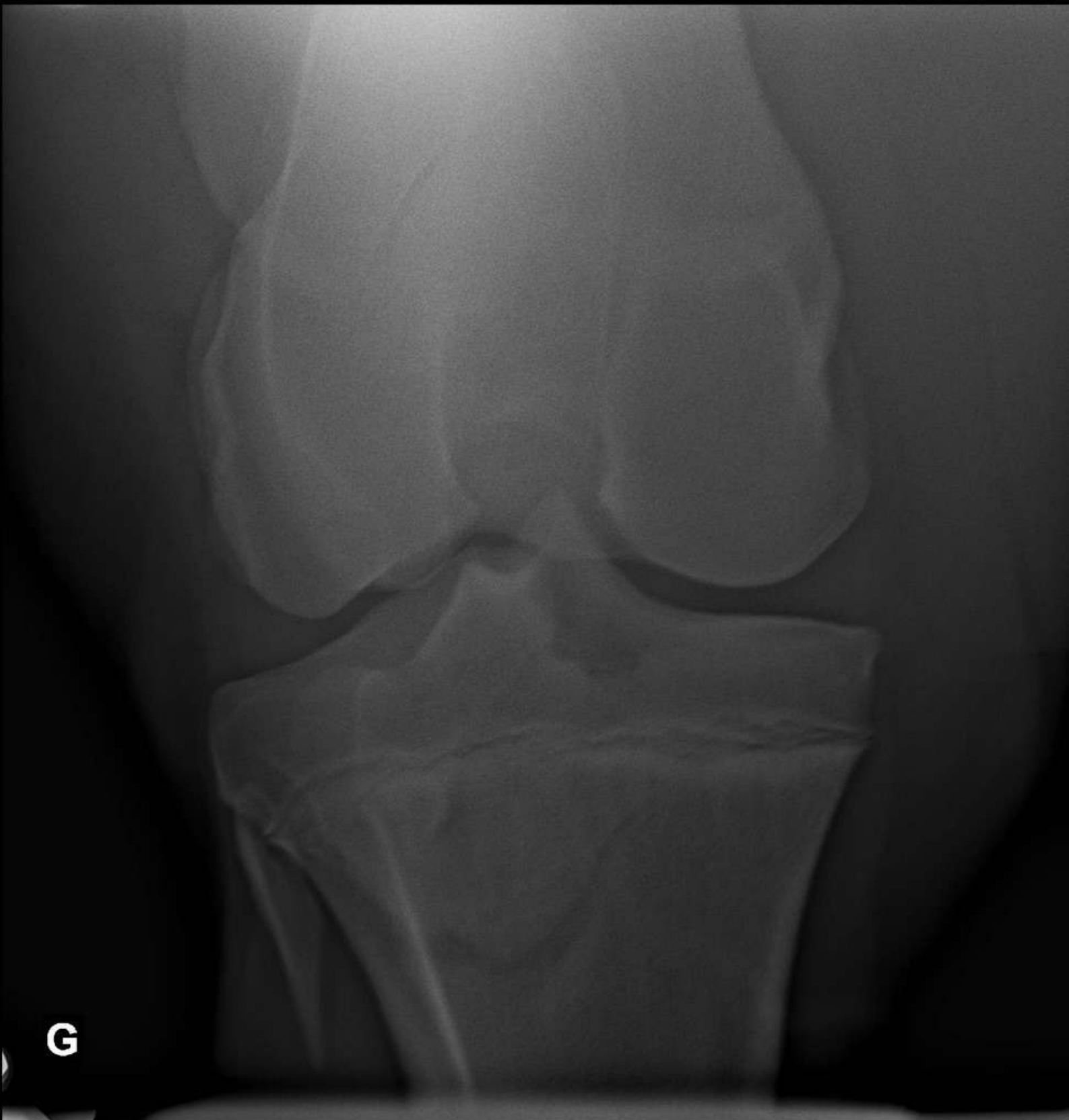


LAURA DE SIJU==
CU00000195

09/10/2023
La Clinique du Cheval



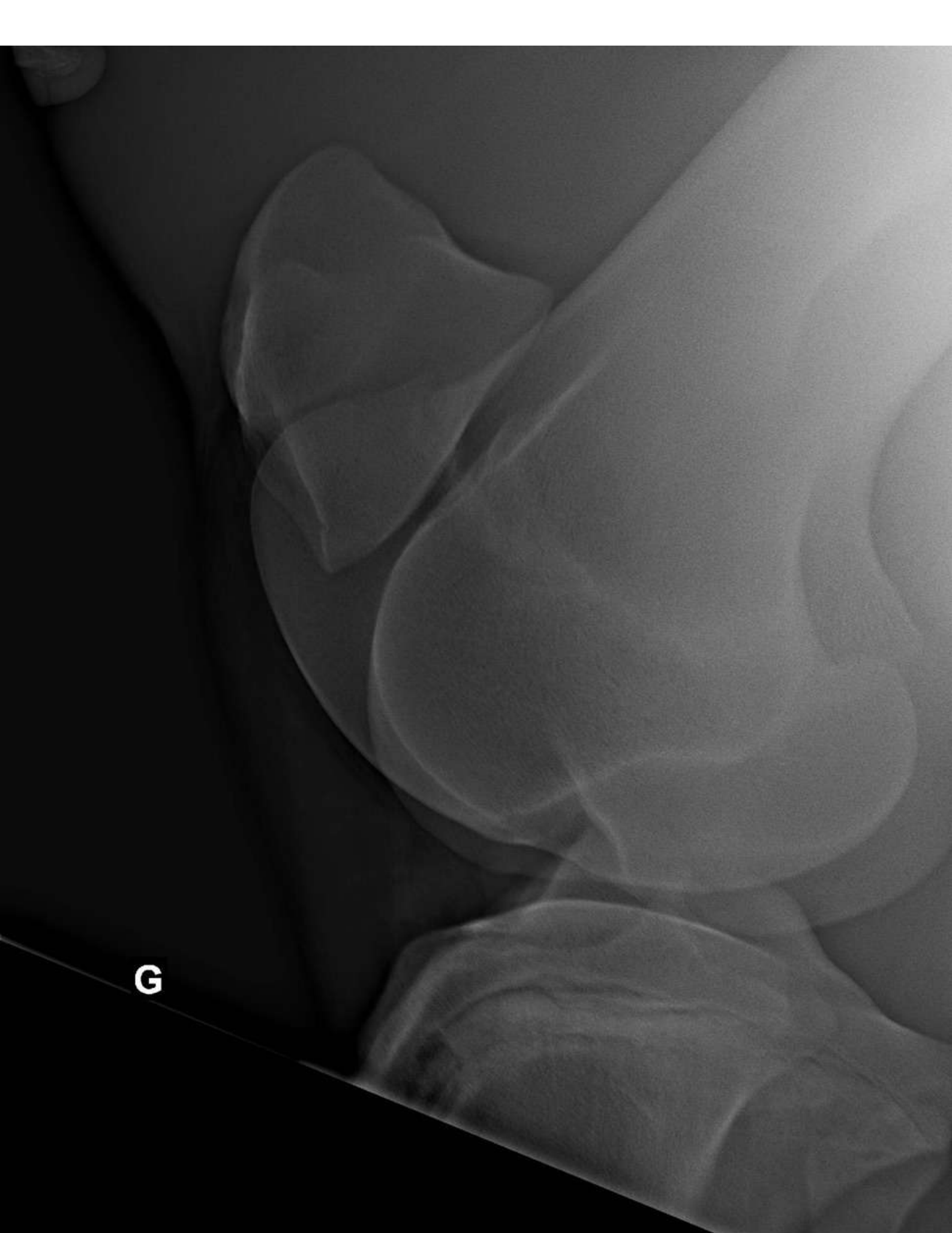
D



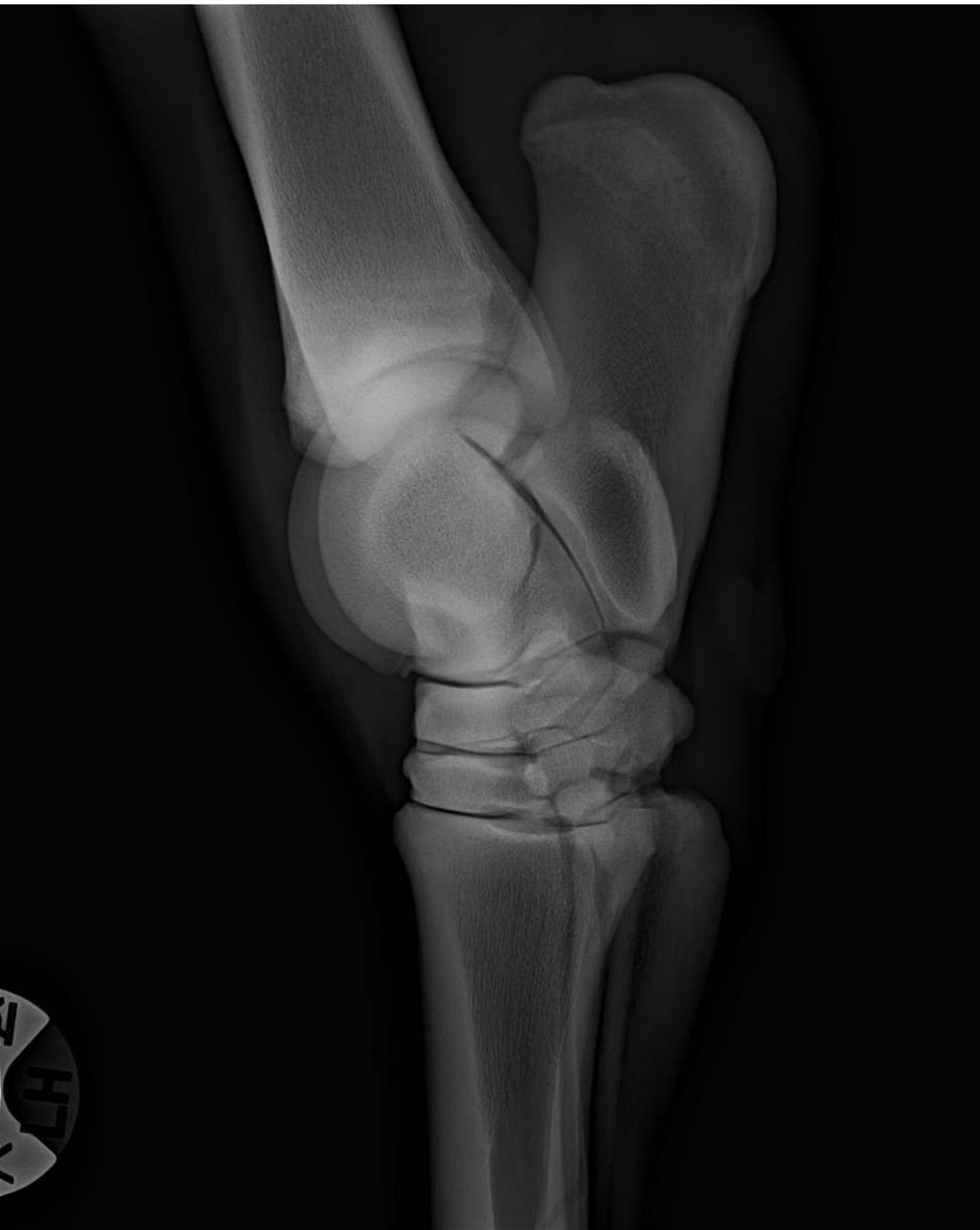G

LAURA DE SIJU==
CU00000195

09/10/2023
La Clinique du Cheval

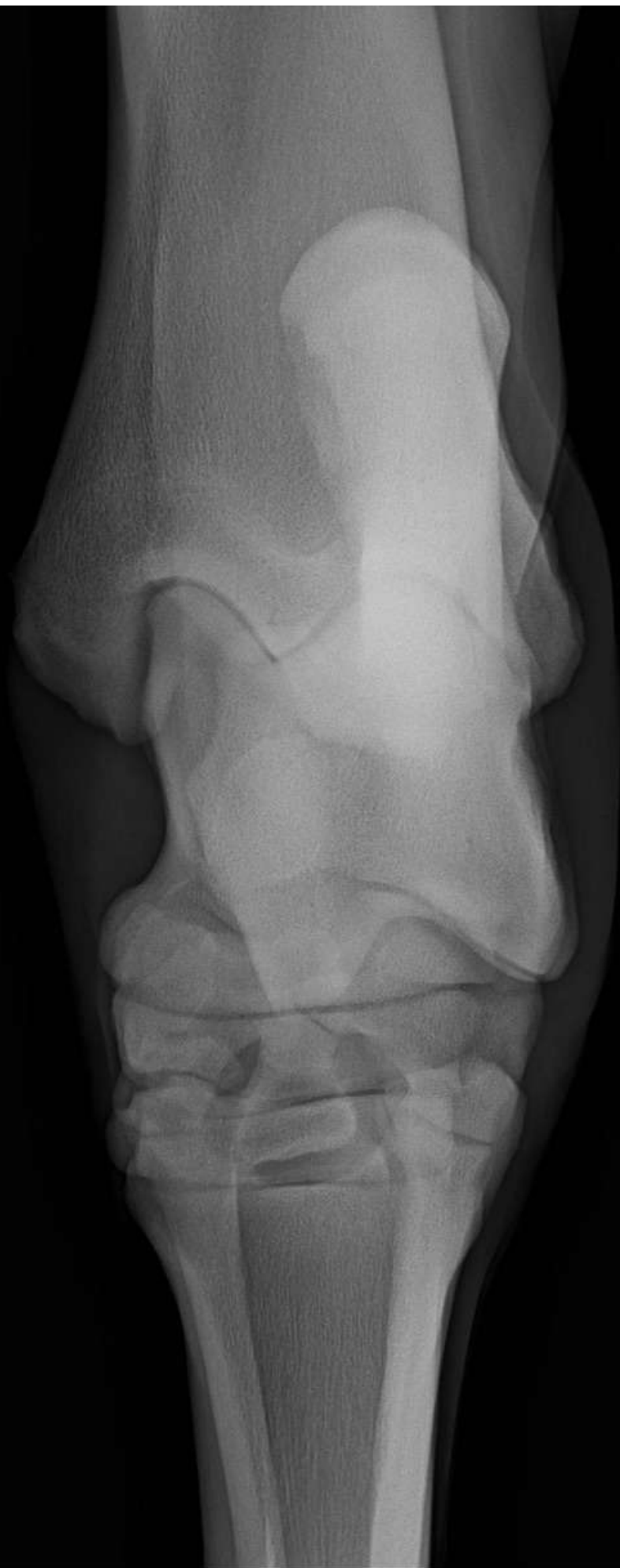

G



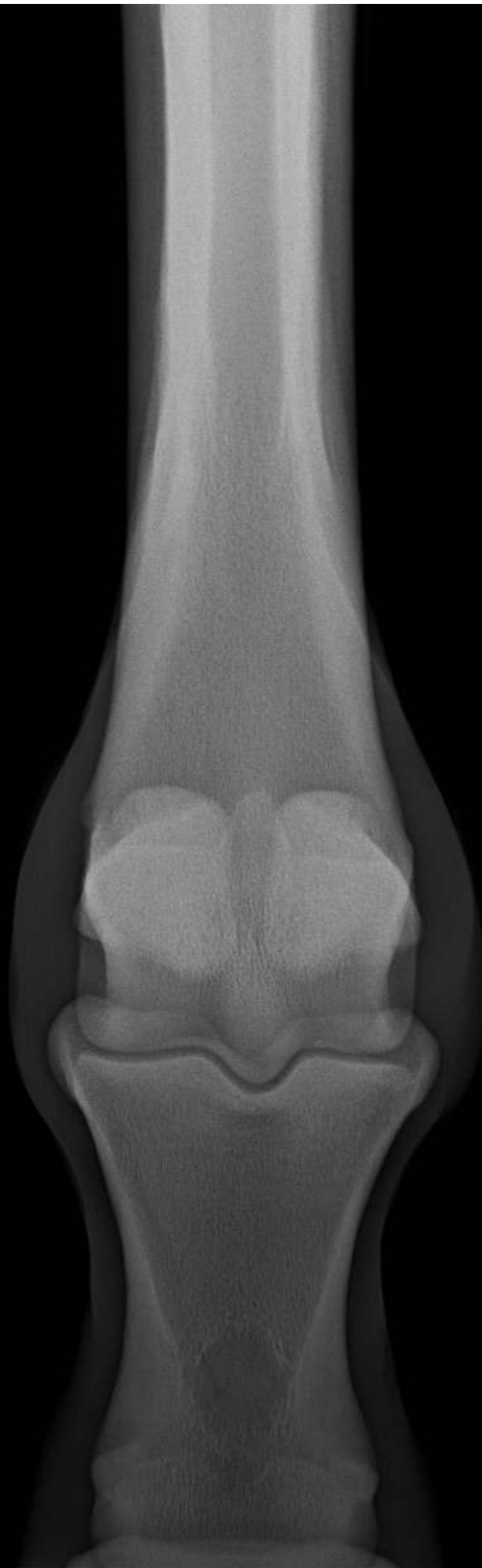LAURA DE SIJU==
CU0000195

09/10/2023
La Clinique du Cheval



LAURA DE SIJU==
CU00000195

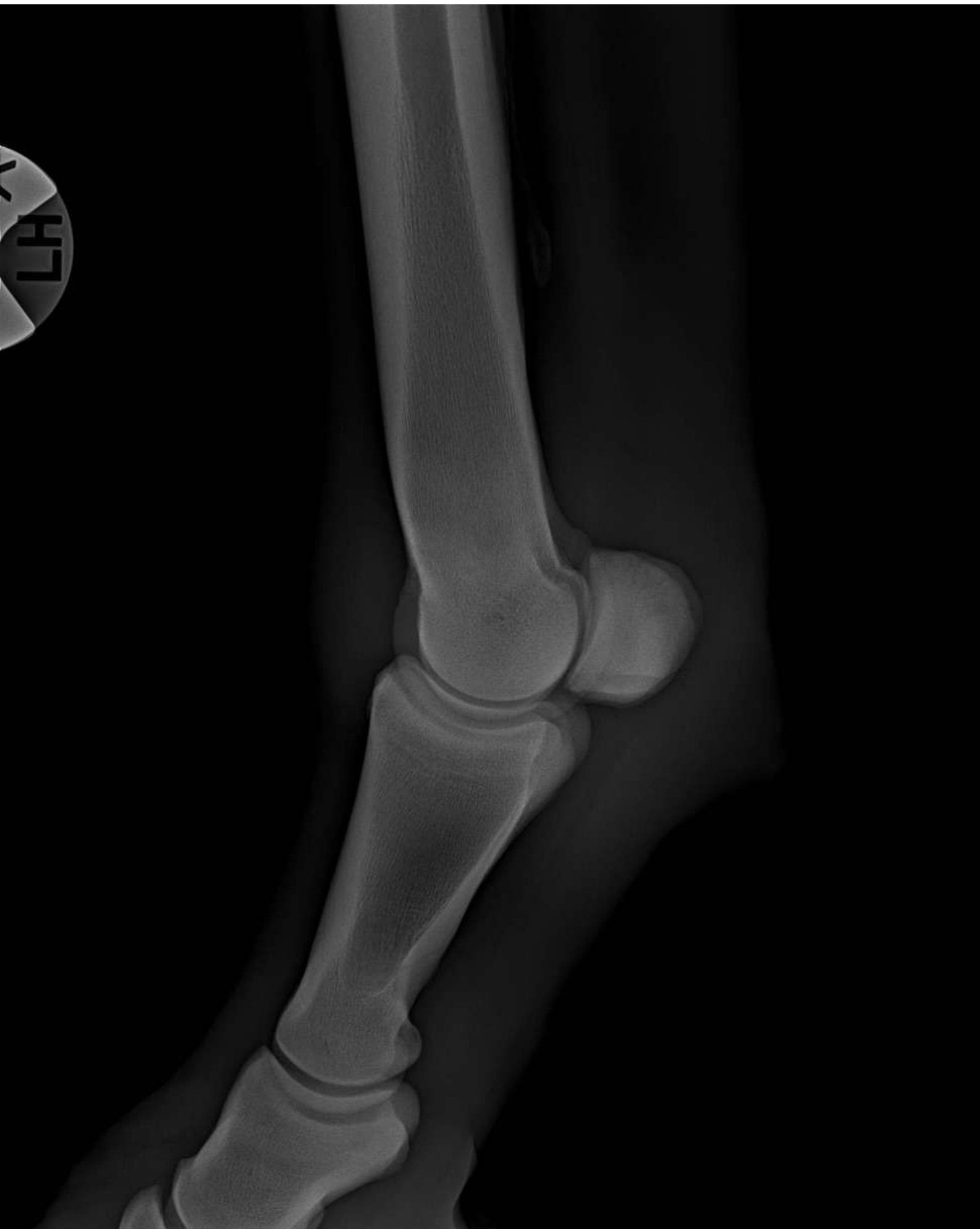09/10/2023
La Clinique du Cheval



LAURA DE SIJU==
CU00000195

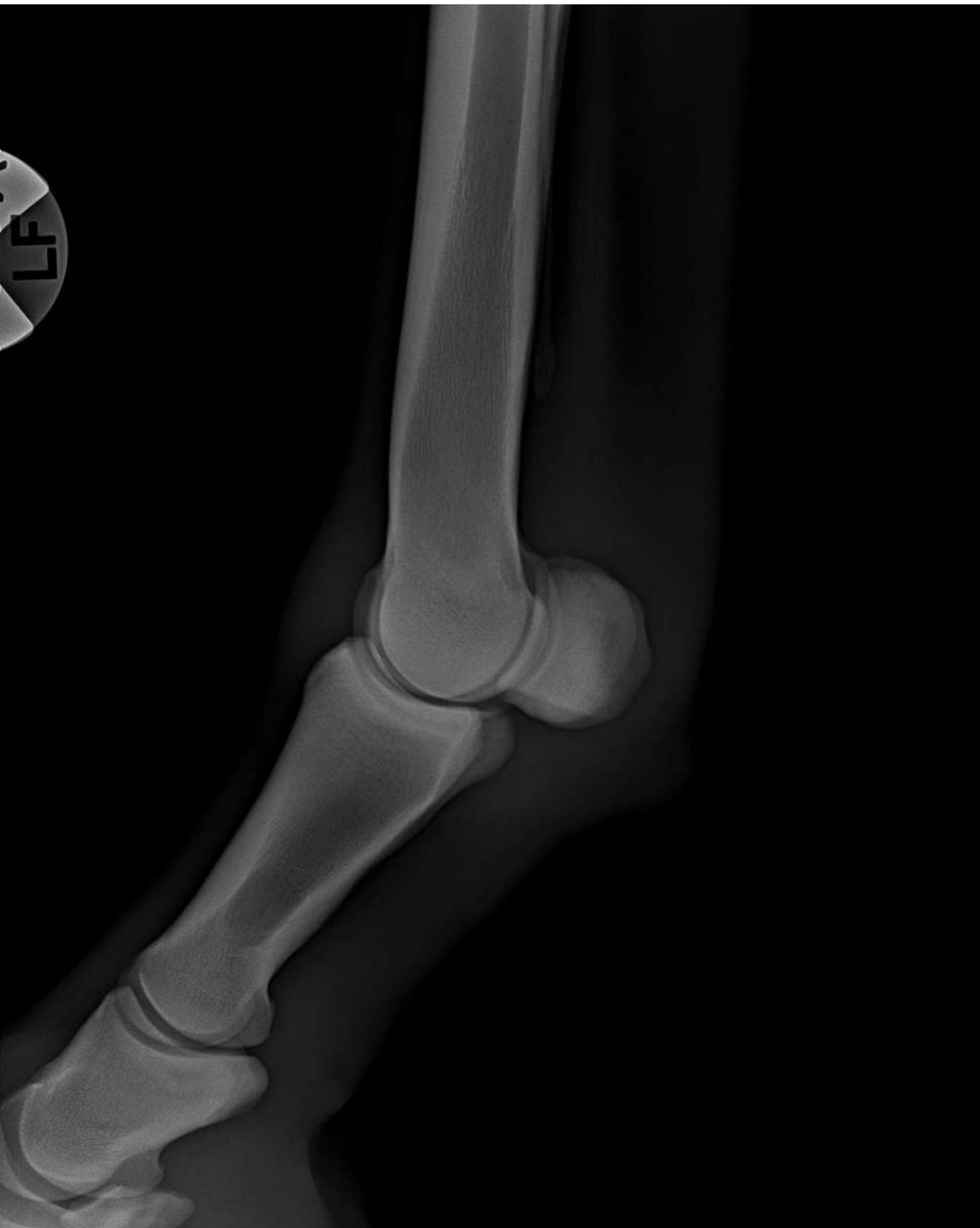09/10/2023
La Clinique du Cheval

LH 17



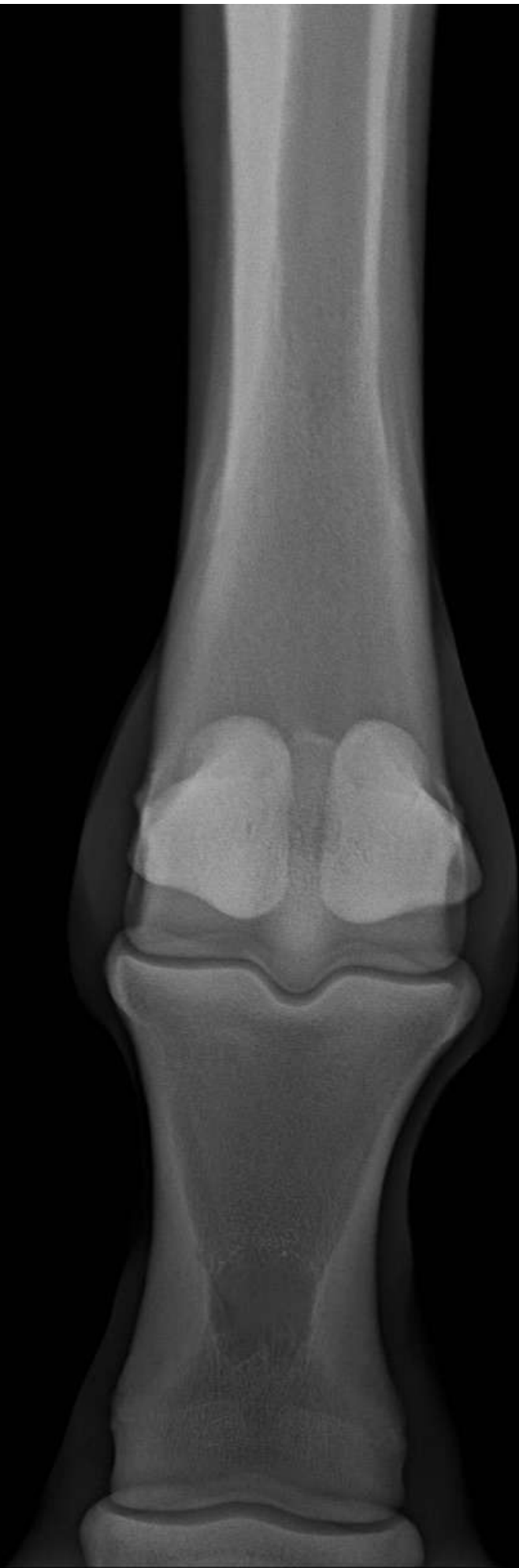LAURA DE SIJU==
CU00000195

09/10/2023
La Clinique du Cheval



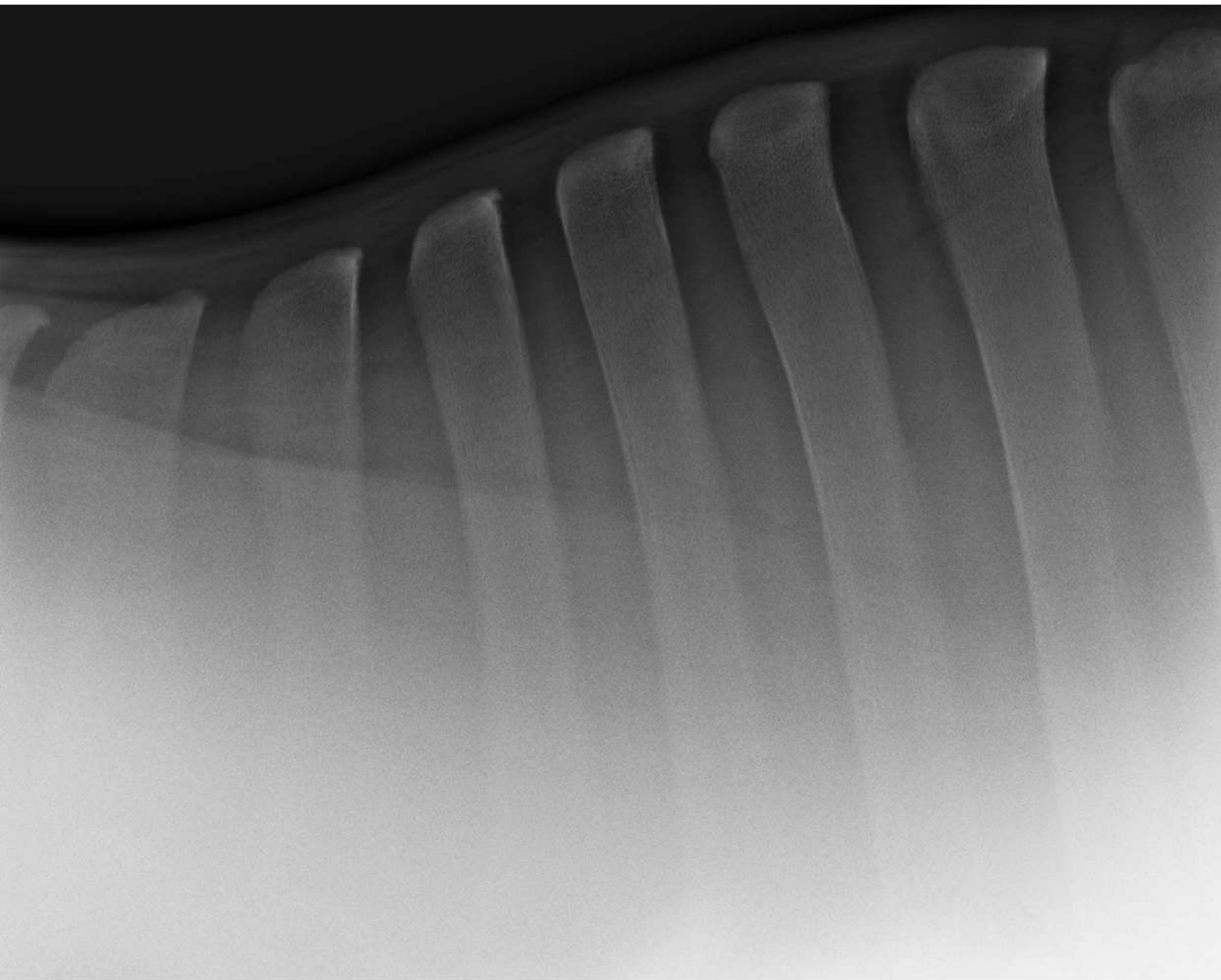
LAURA DE SIJU==
CU00000195

09/10/2023
La Clinique du Cheval



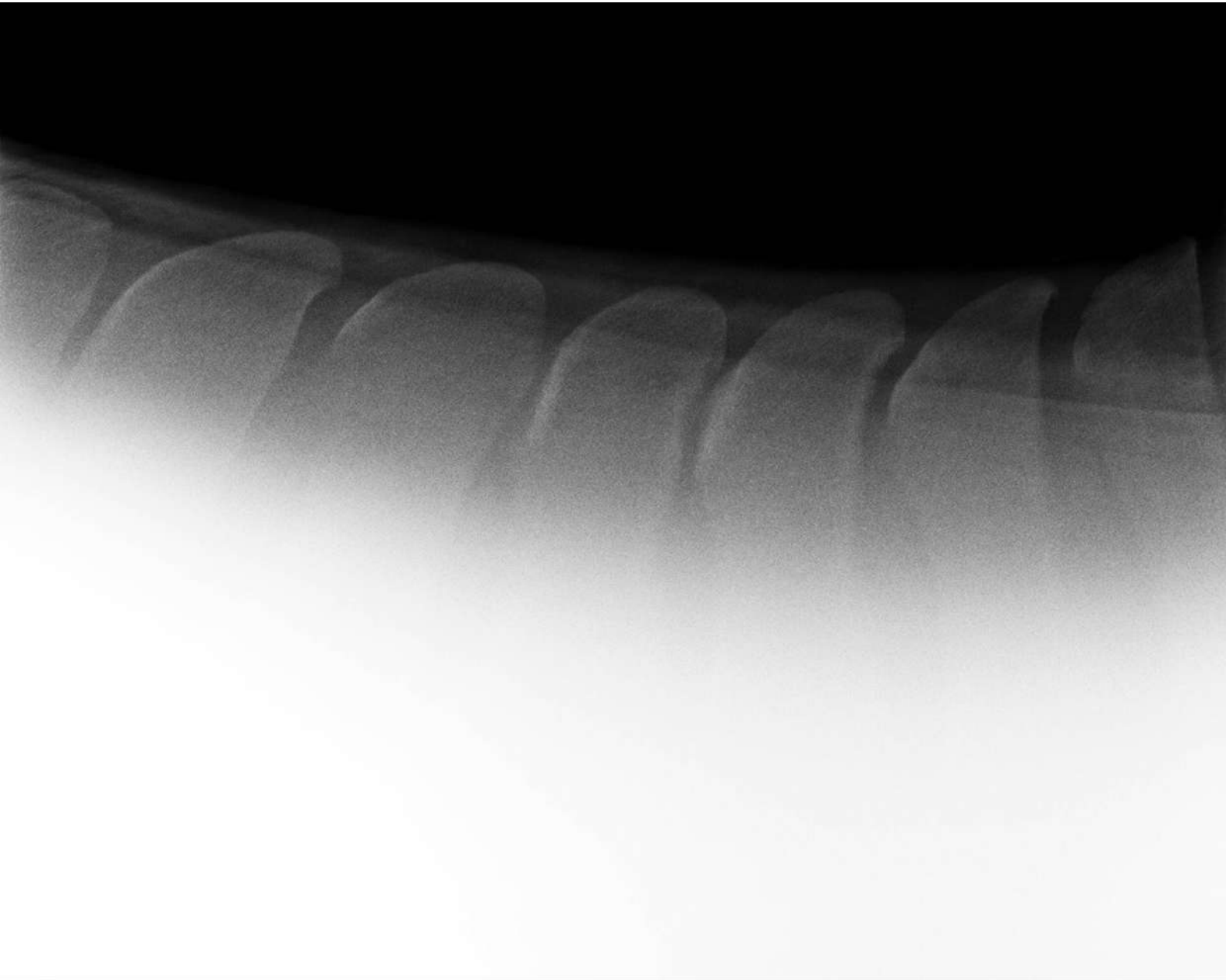
LAURA DE SIJU==
CU00000195

09/10/2023
La Clinique du Cheval



LAURA DE SIJU==
CU00000195

09/10/2023
La Clinique du Cheval



LAURA DE SIJU==
CU00000195

09/10/2023
La Clinique du Cheval