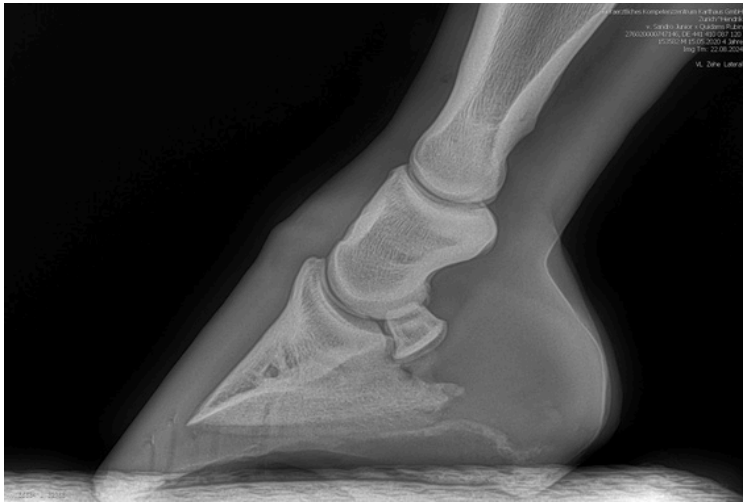
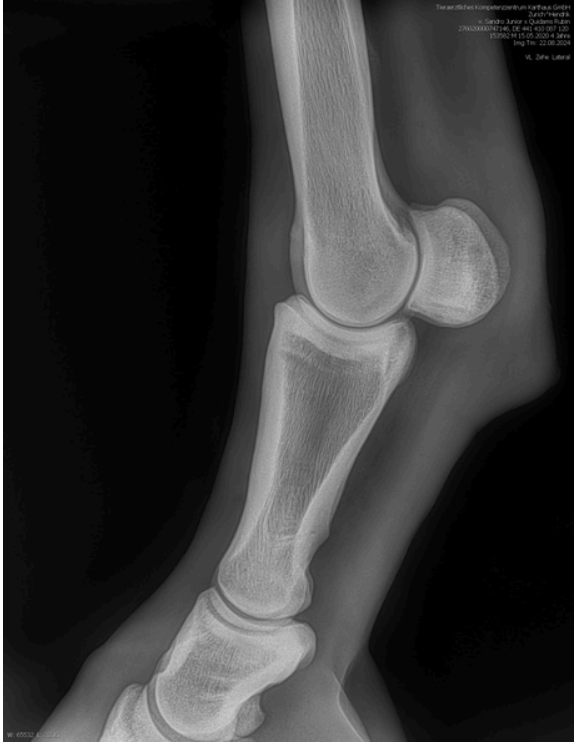
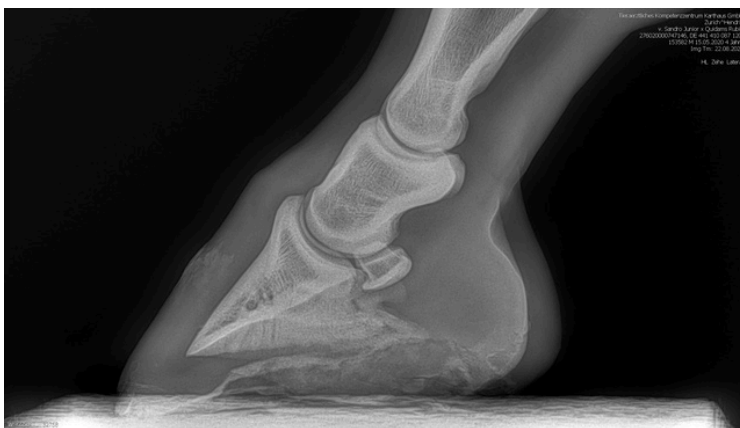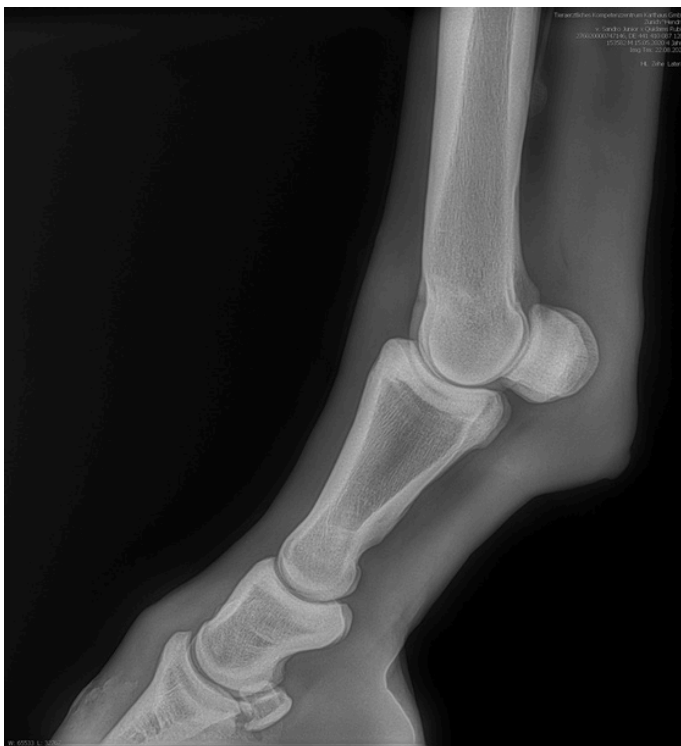www.thespinejournal.com | Volume 25(11)
November 2014
Spine, Spinal Cord & Rehabilitation
25(11) NOVEMBER 2014
ISSN 1078-1236
Page No. 2250-2254
© The Author

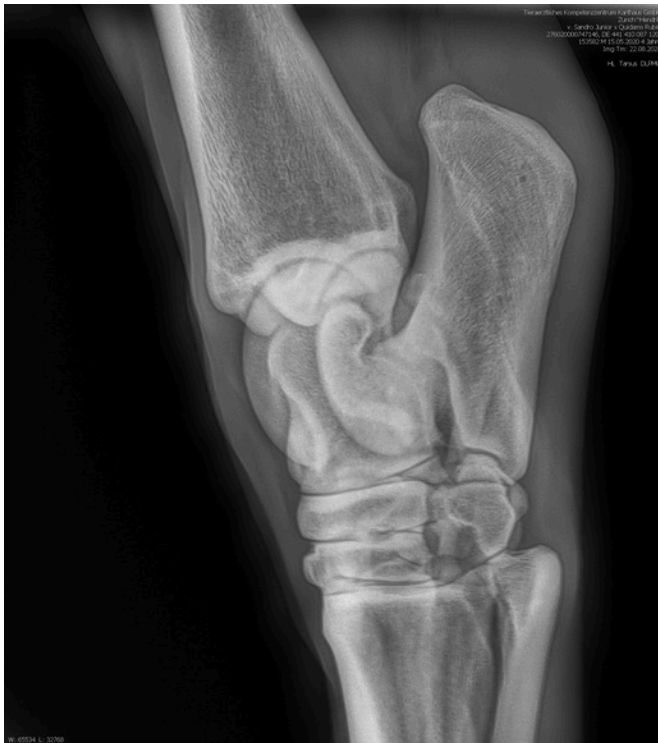

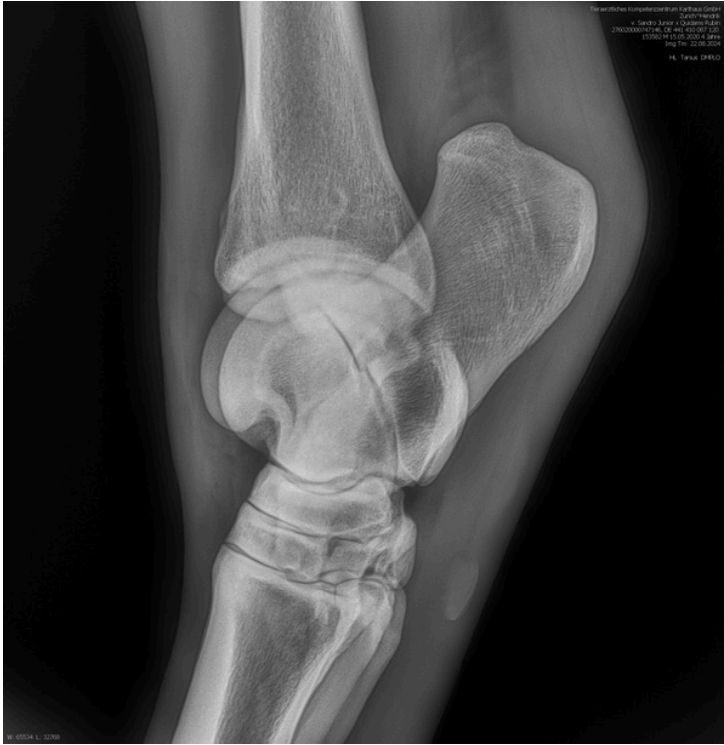The acquisition parameters are:
Date: 2014-08-28
Time: 14:14:14
Patient: 10141414
Study: 10141414
Series: 10141414
Image: 10141414
10141414



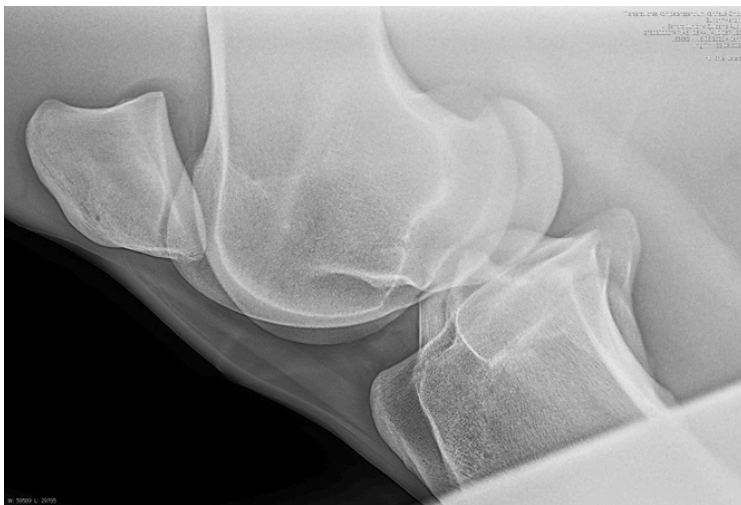www.helios.com/CTScan/3D/3D011216
CT Scan: 3010011216
2762000071740, DE 463 402 507 120
1216001 11 11 2016 12:04:04 PM
img file: 3D011216
10 30m Laser



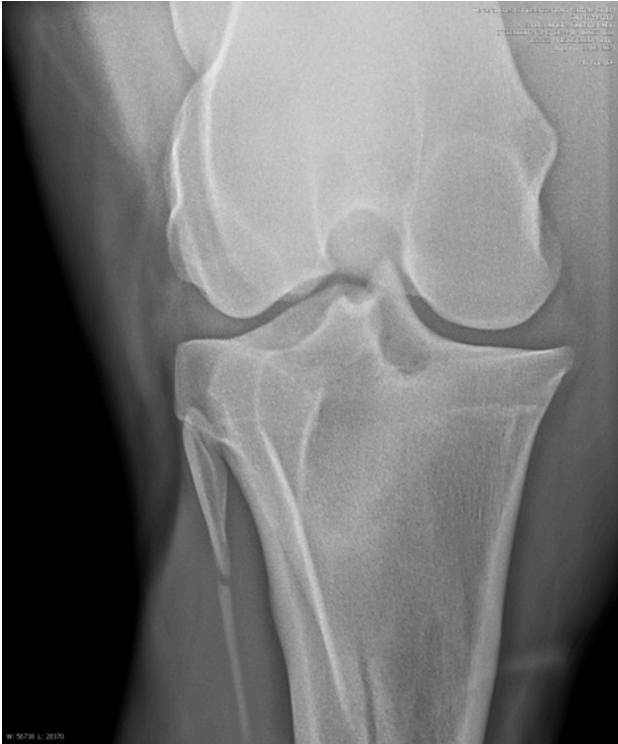


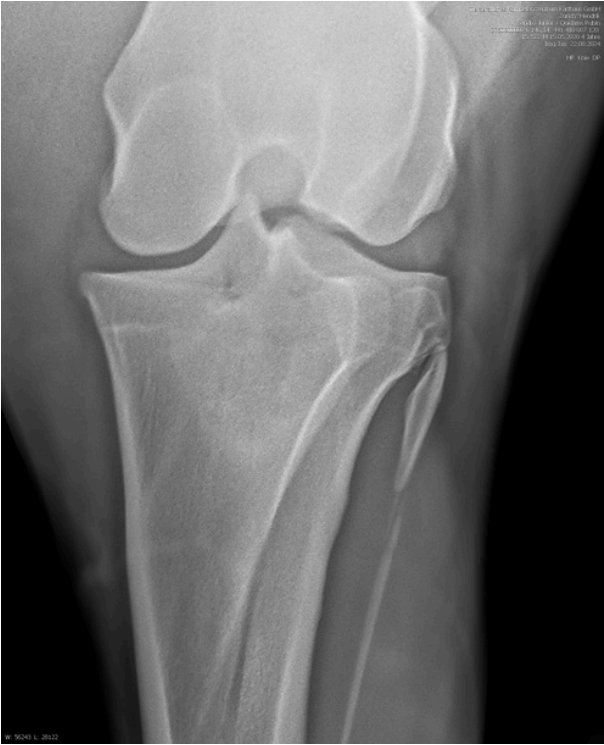
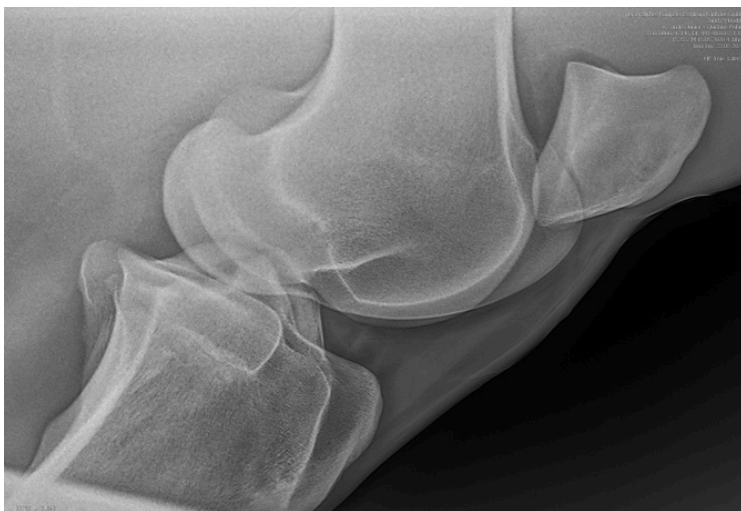
The website www.dcm4chee.org is a freely available
DICOM viewer
© 2013-2014 by Leica Camera AG
2900000171740, CT 441 432 007 220
P1052014121622014 8 24809
img Tim: 22.08.2014
14_Taxus_04850

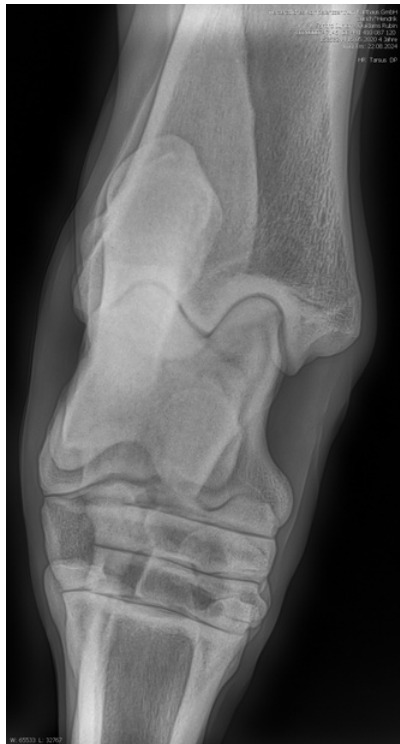

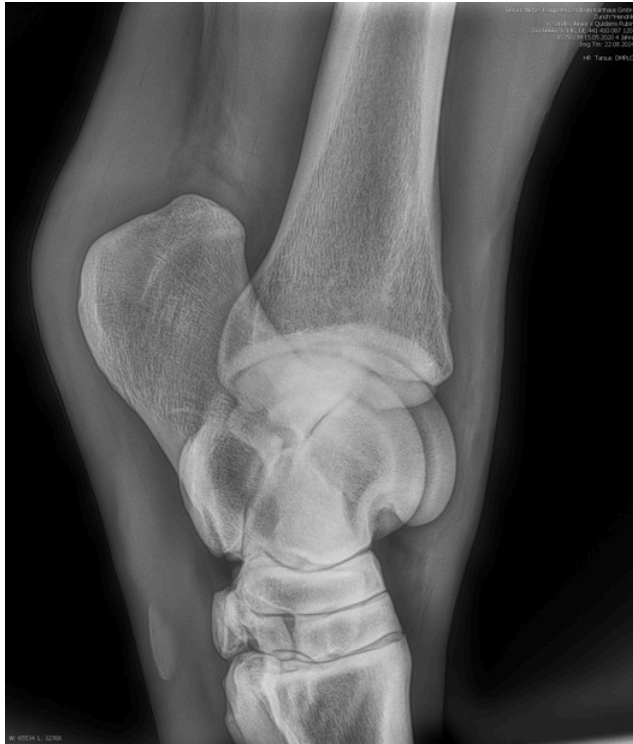
THE UNIVERSITY OF CHICAGO
LIBRARY
3100 EAST 57TH STREET
CHICAGO, ILLINOIS 60637
TEL: 773-936-3000
WWW.CHICAGO.LIBRARY.EDU

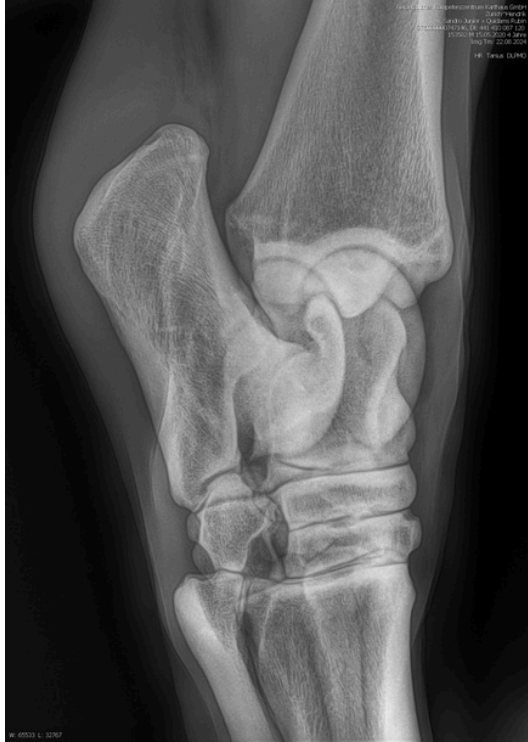


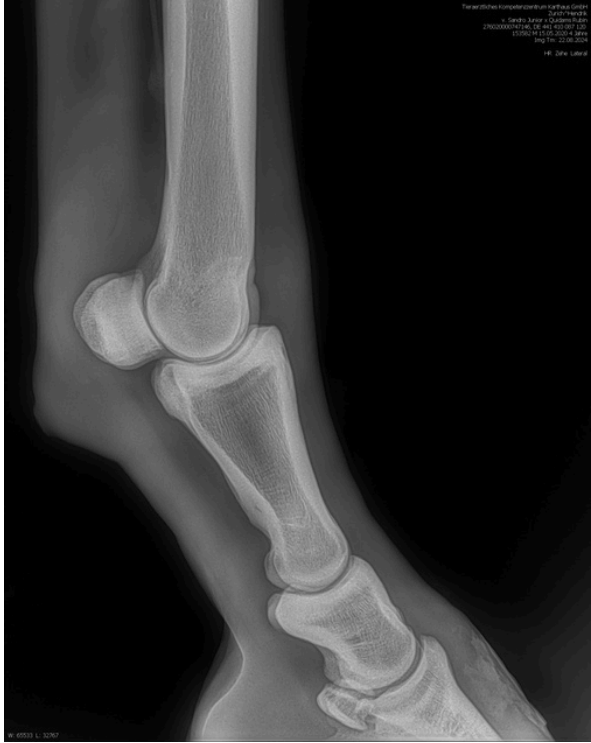




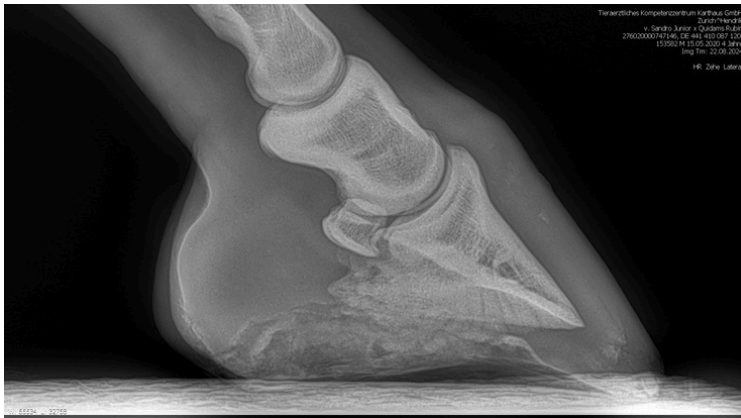




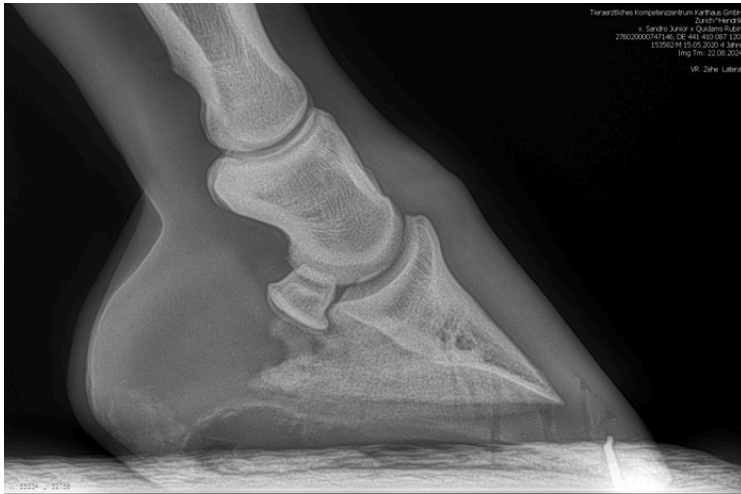

The worldwide leader in orthopedic care
Dr. Smith, MD
20000000000, 0000000000
10000000000, 0000000000
10000000000, 0000000000
10000000000, 0000000000
10000000000, 0000000000

© 2000 L. Smith





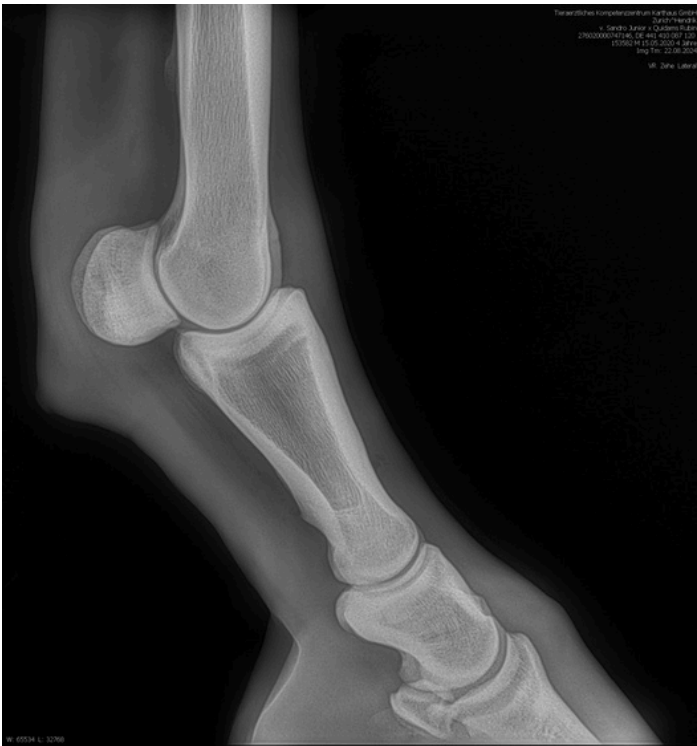Tierärztliches Hospital Dr. med. vet. G. G. G. G.
Zurich, Switzerland
© 2008, 2009, 2010, 2011, 2012
27620000747146, CE 041 401 087 120
15/00018, 15/00 20018, 15/00
Imp. Tim. 02.08.2008

VR: Zahn, Lateral

0002-12710

Examen de radiografía digital de la rodilla
05/27/2024
Centro de Imágenes Médicas
278000007416, (0-40) 423-007 430
15000 64 150-2004-0004
Imag. Tr.: 22.08.2024

V: 20ra. Lateral



© 2024 - 1 - 12/2024





