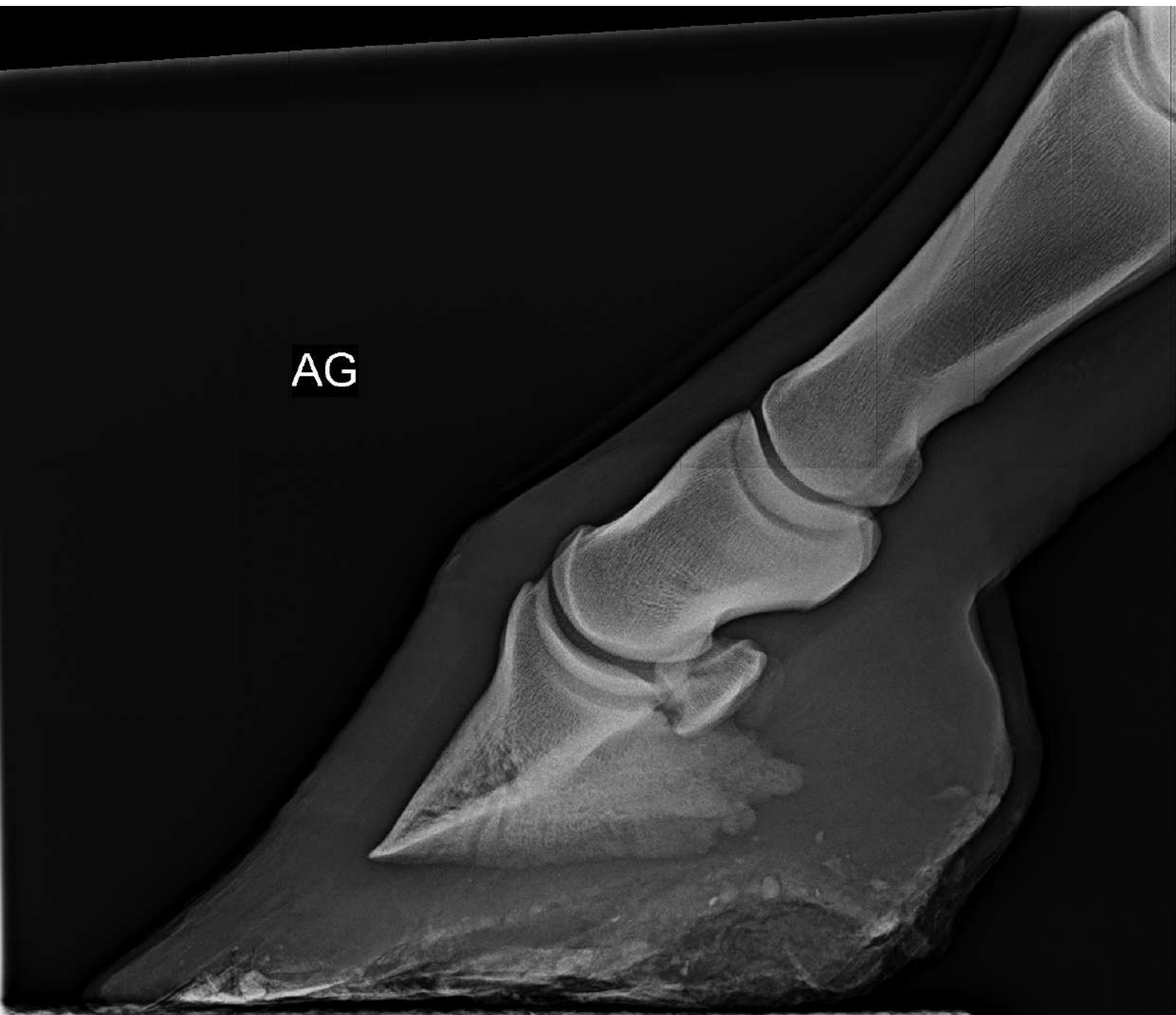

AD

LEXLESS DU GUE  
21367765S

11/8/2024 12:00:00 AM  
Docteur Sonia ROYER



AG

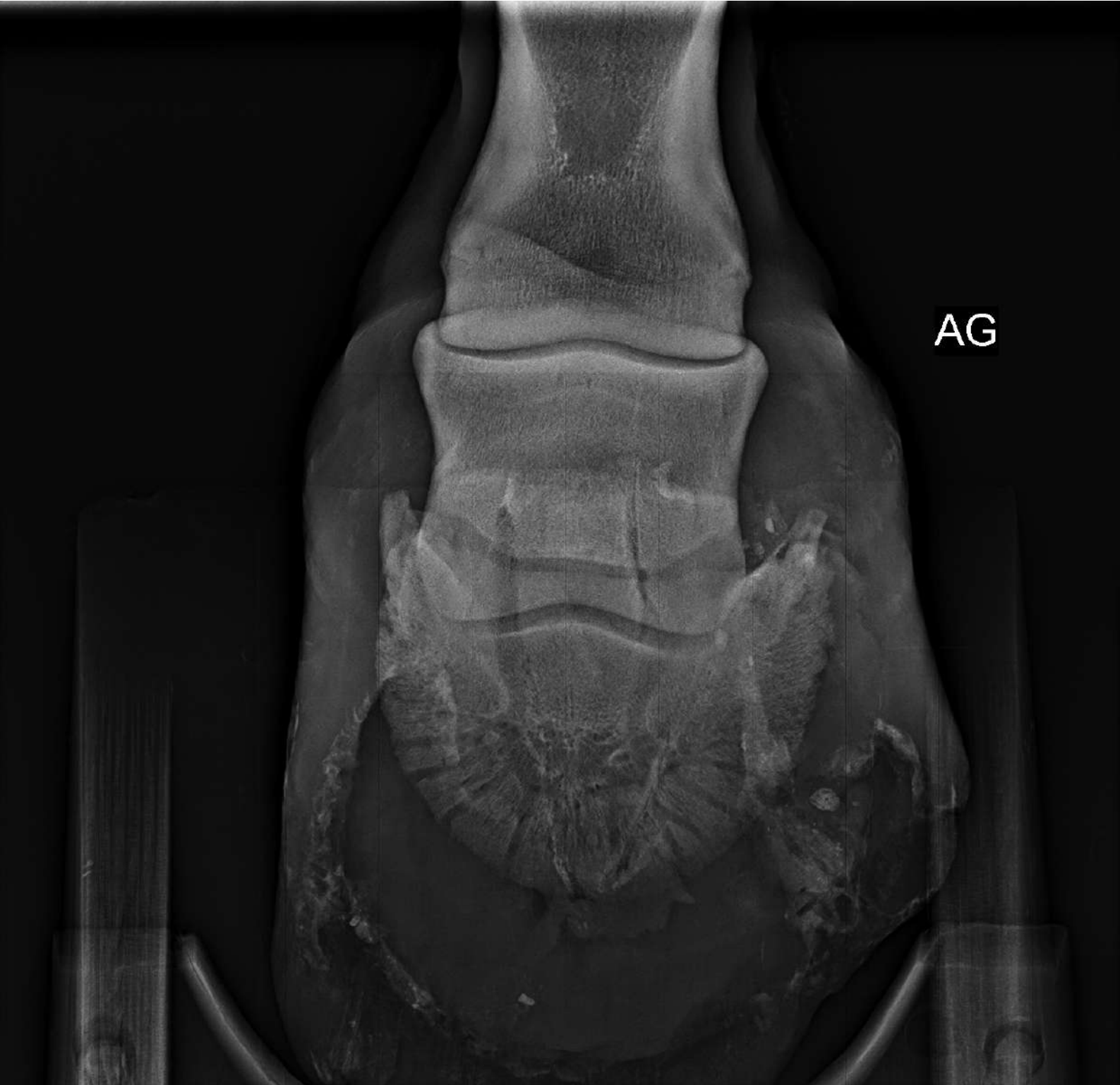

AD

This is an anteroposterior (AP) radiograph of the lumbar spine. The vertebrae are clearly visible, and there is a distinct fracture of the vertebral body of the fifth lumbar vertebra (L5). The fracture line is visible on the right side of the image, extending through the vertebral body. The surrounding soft tissue and intervertebral discs appear relatively normal, though there is some slight narrowing of the disc spaces. The overall image is in grayscale, typical of a radiograph.

LEXLESS DU GUE  
21367765S

11/8/2024 12:00:00 AM  
Docteur Sonia ROYER

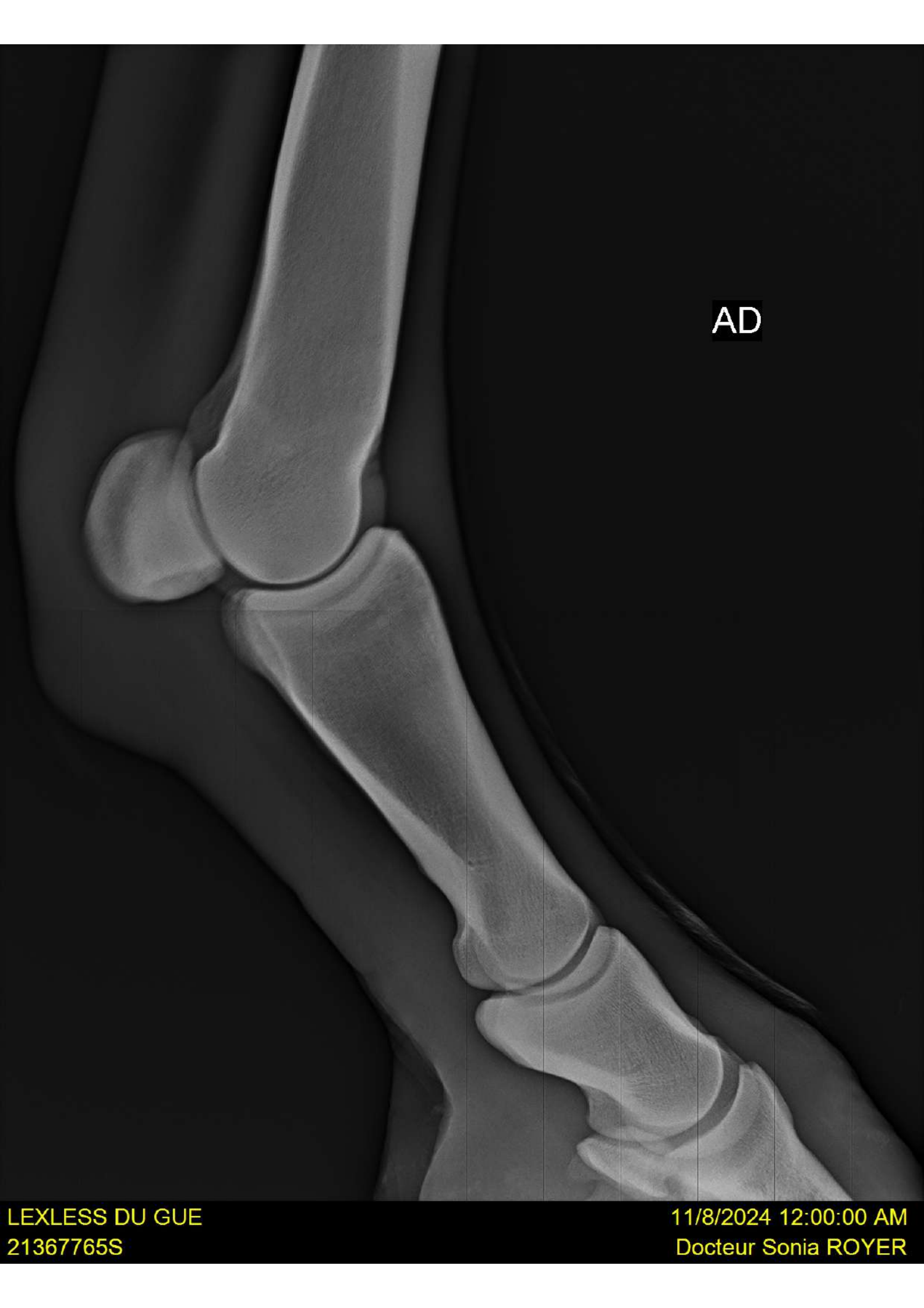

AG

LEXLESS DU GUE  
21367765S

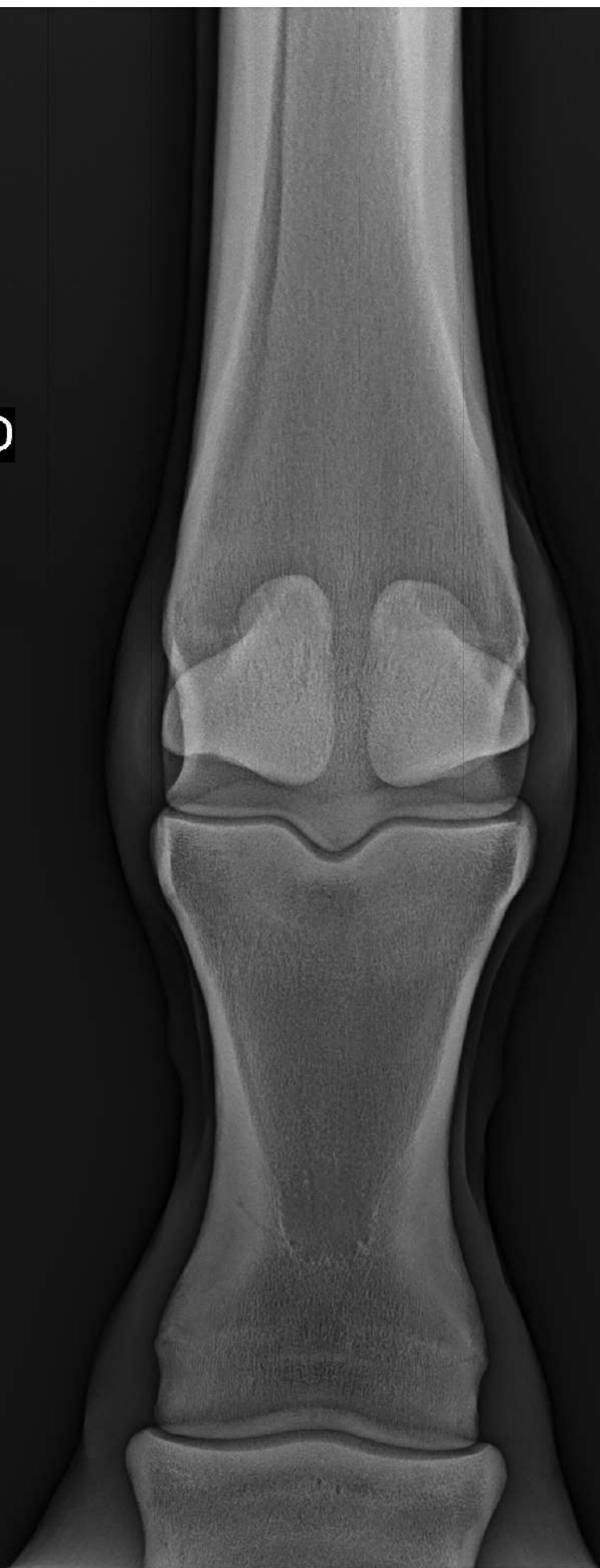11/8/2024 12:00:00 AM  
Docteur Sonia ROYER

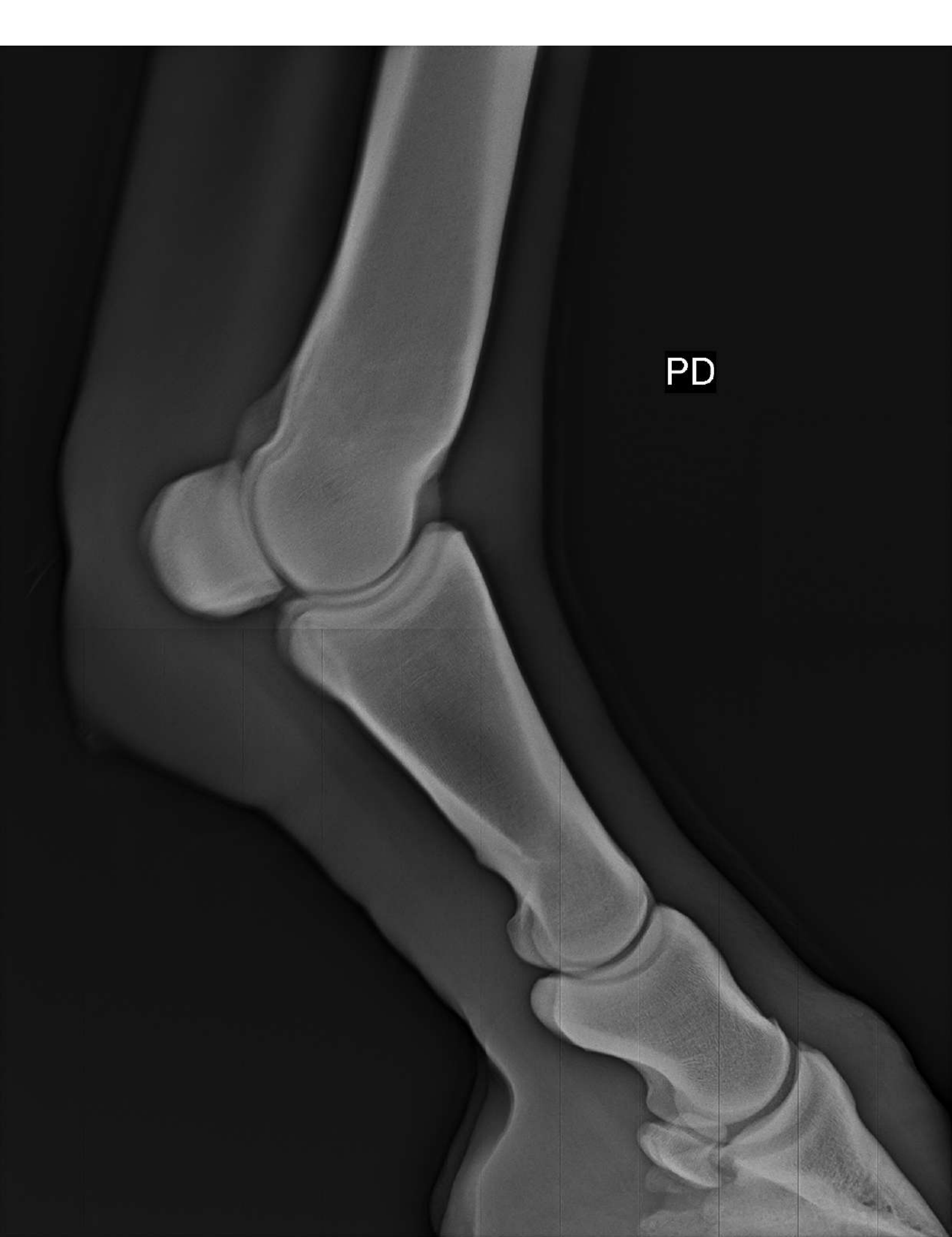



AD

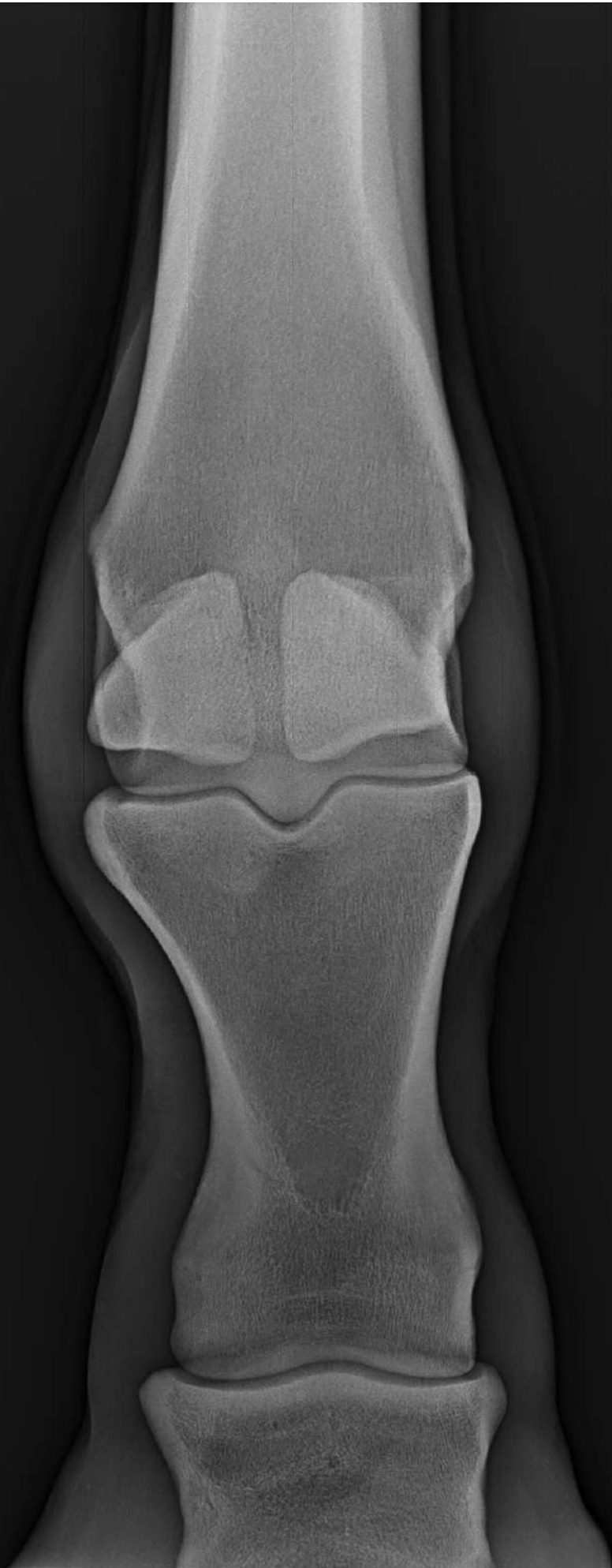AD



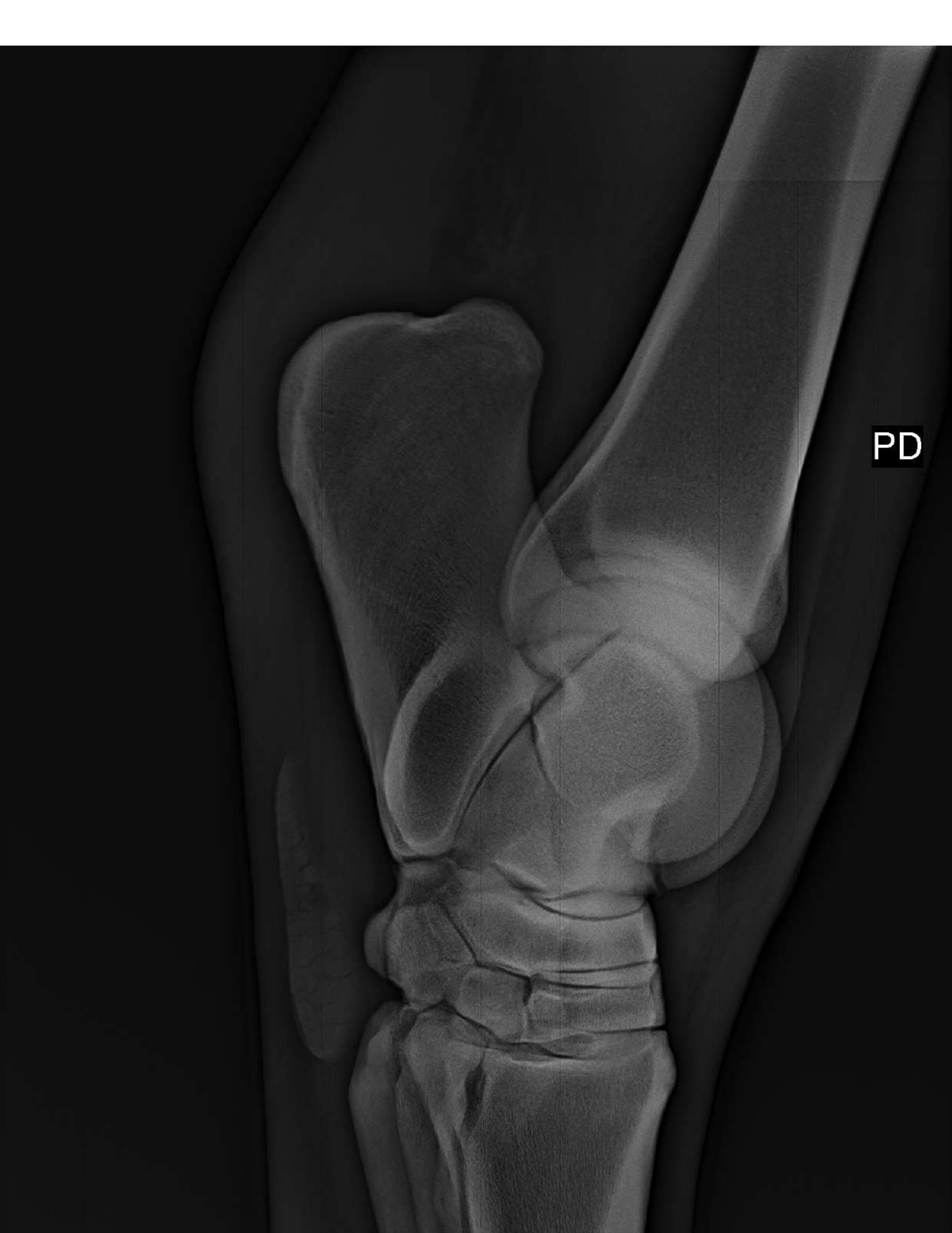


PD

PD

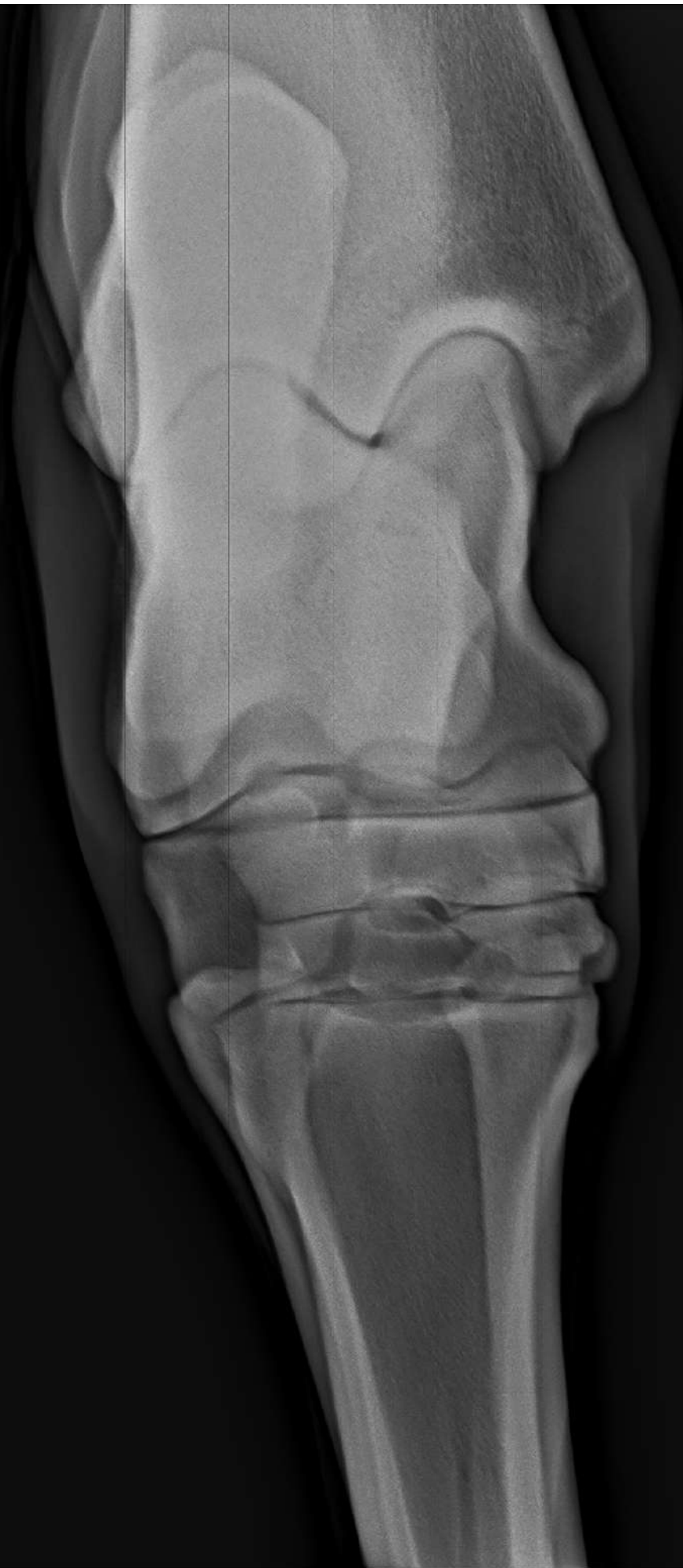


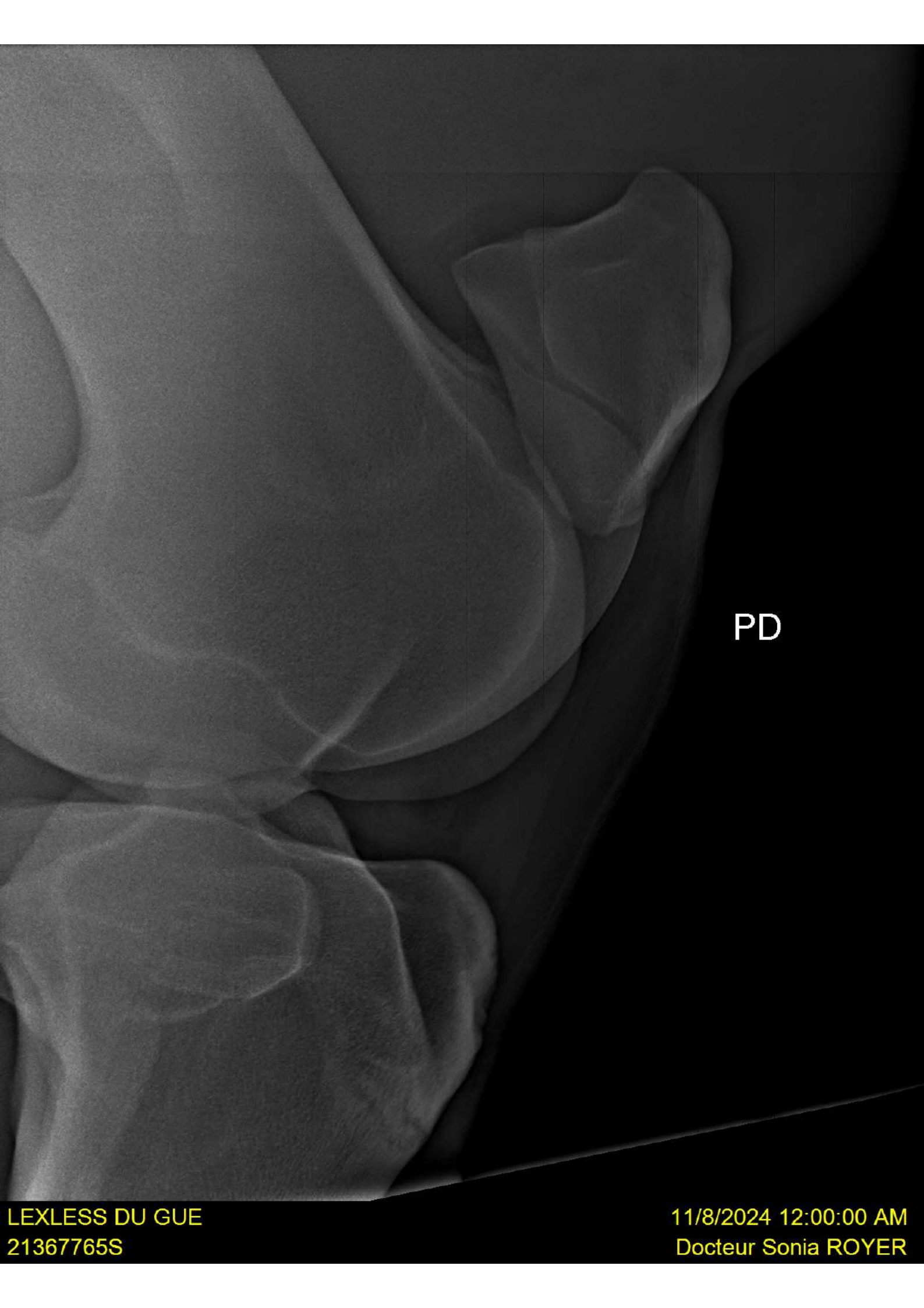


PD

PD

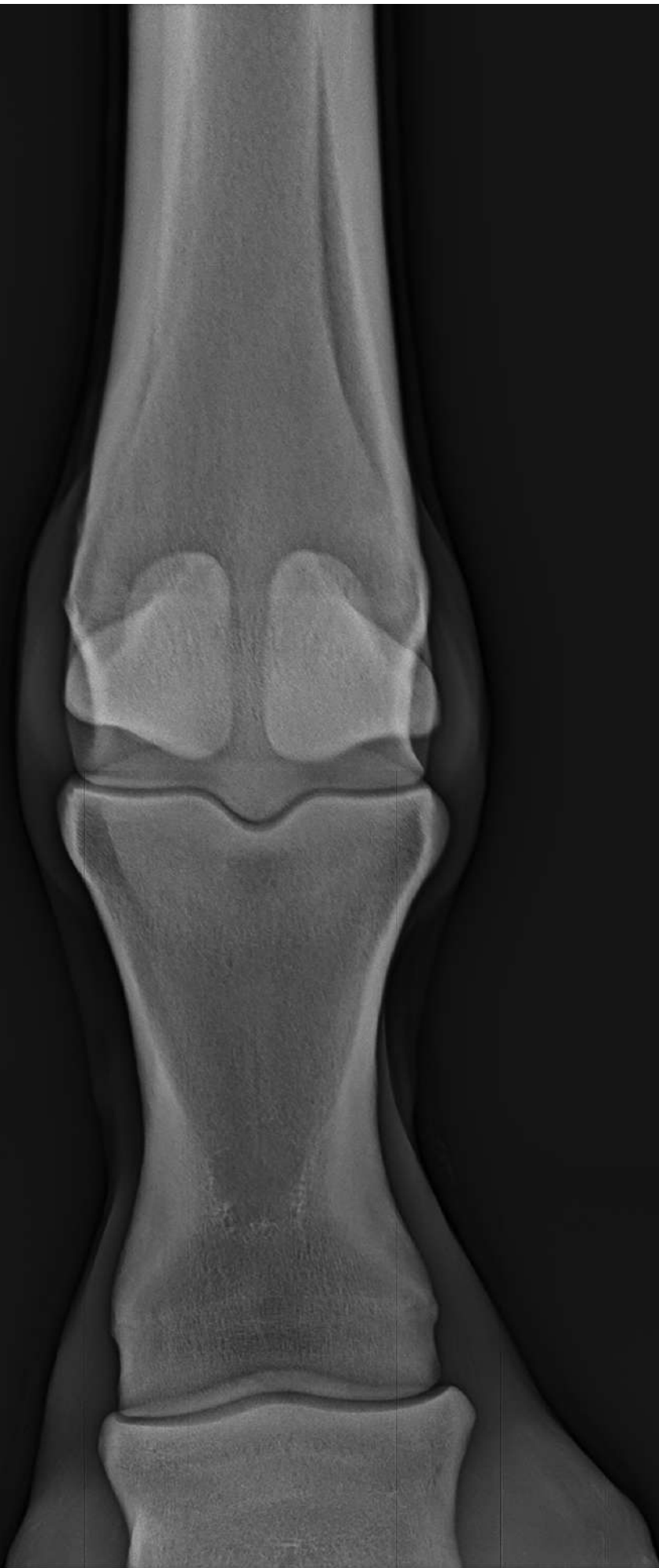



PD

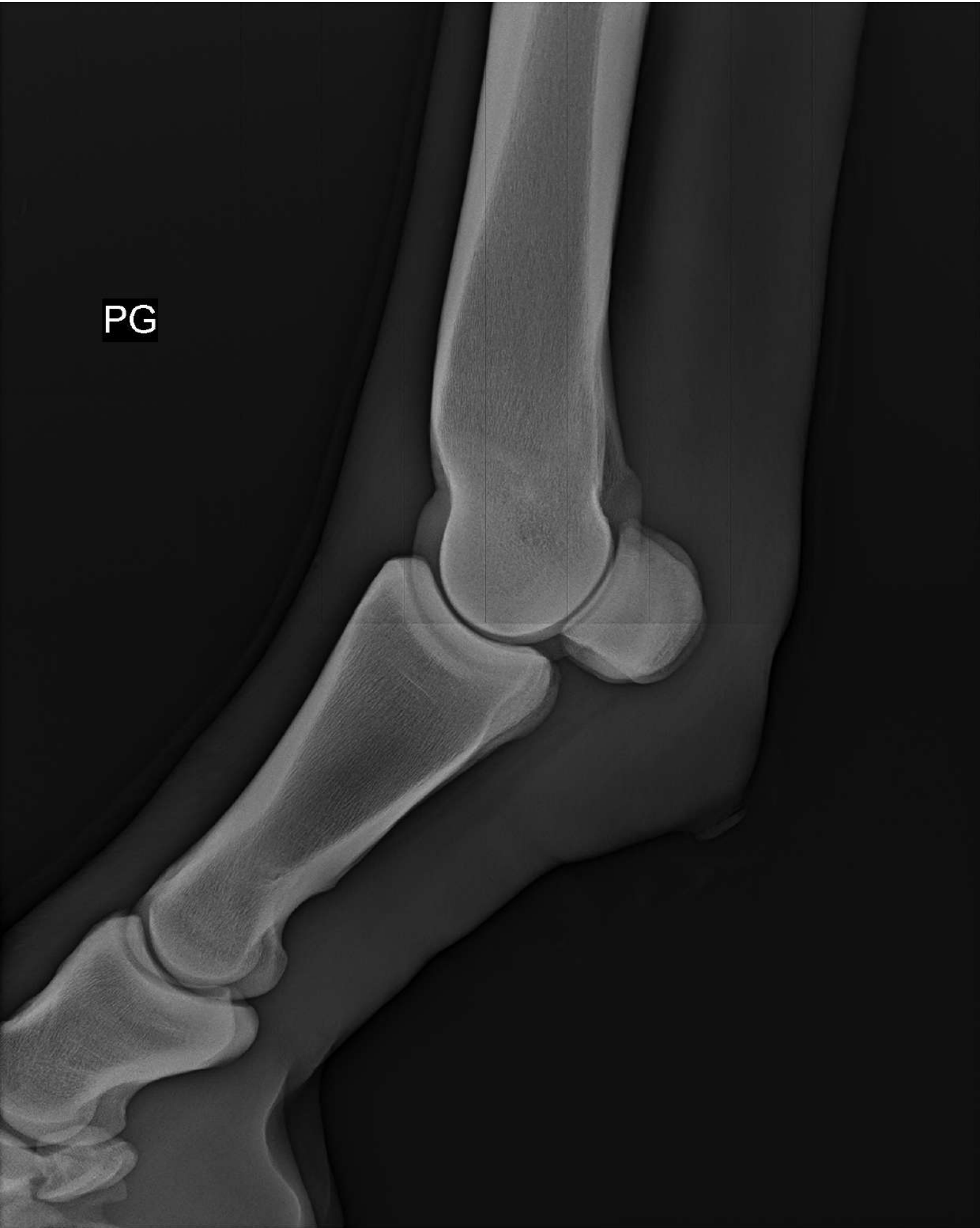AG

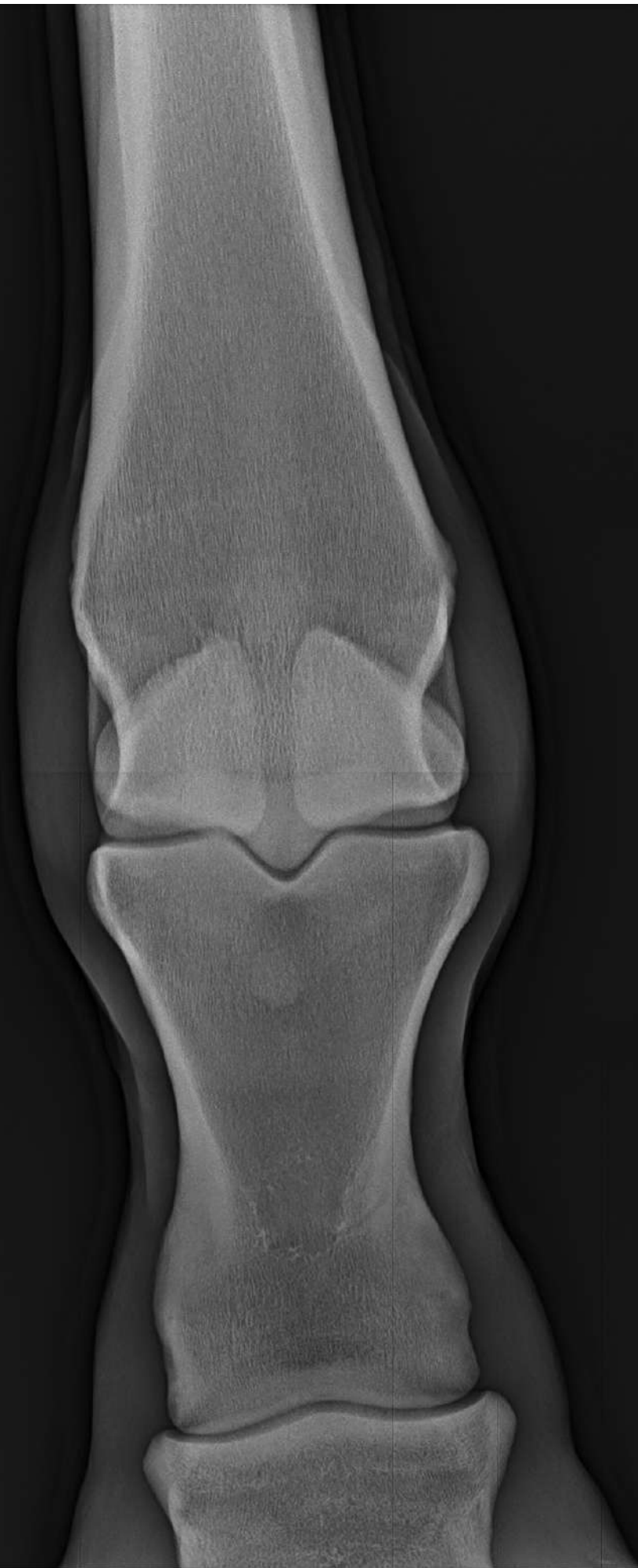



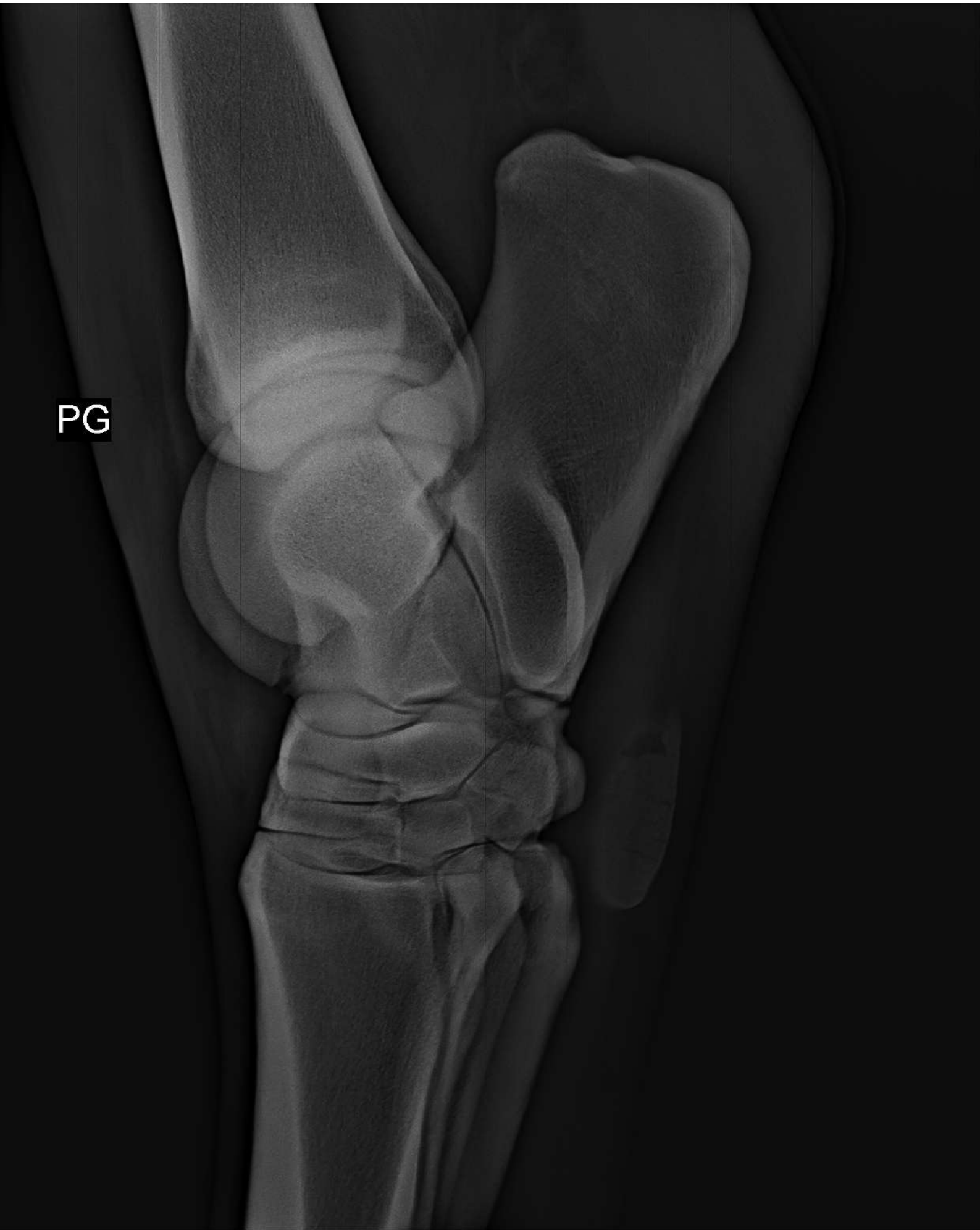
AG

PG



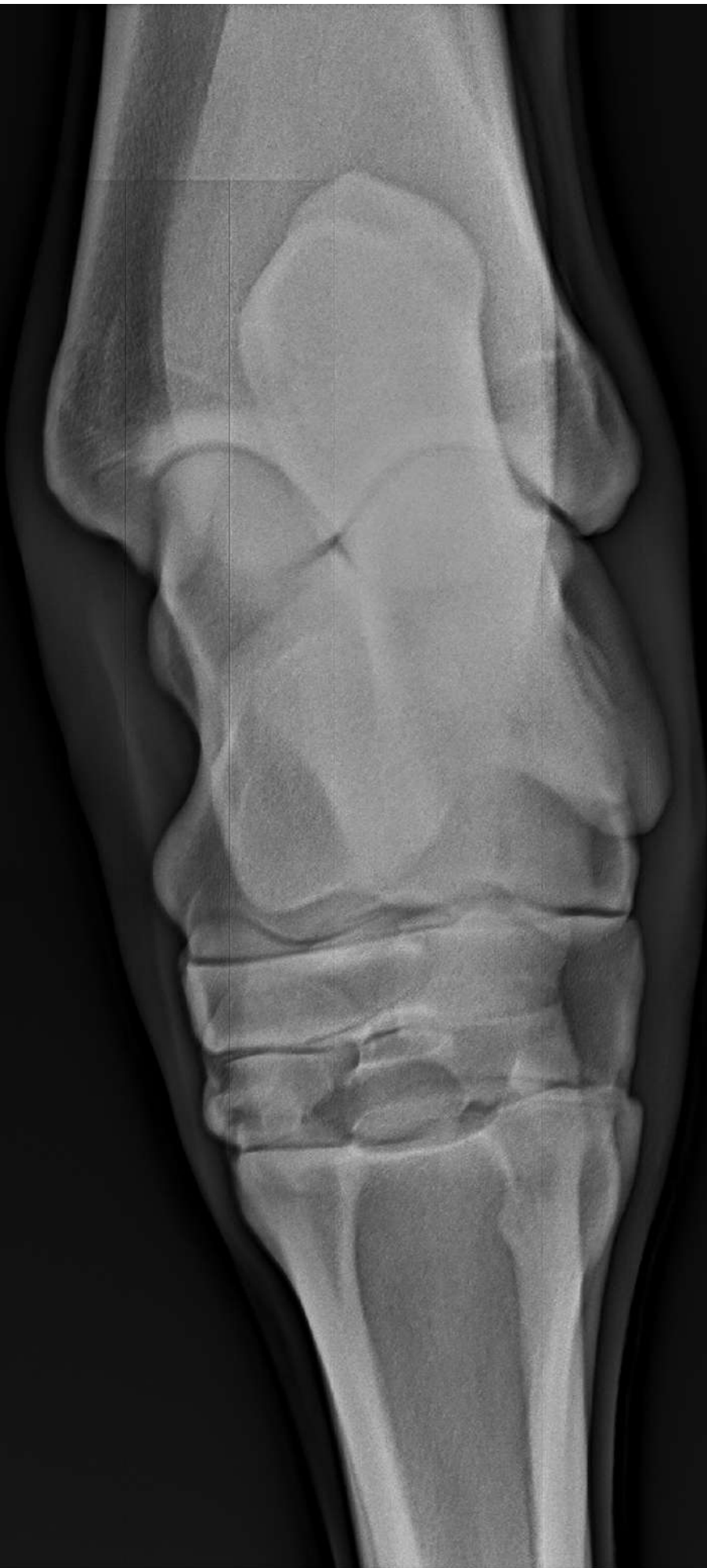

PG



PG





PG

PG



PG





PD