



AG/LF

LIMALAYA DE RIVERLAND
SCEA RIVERLAND

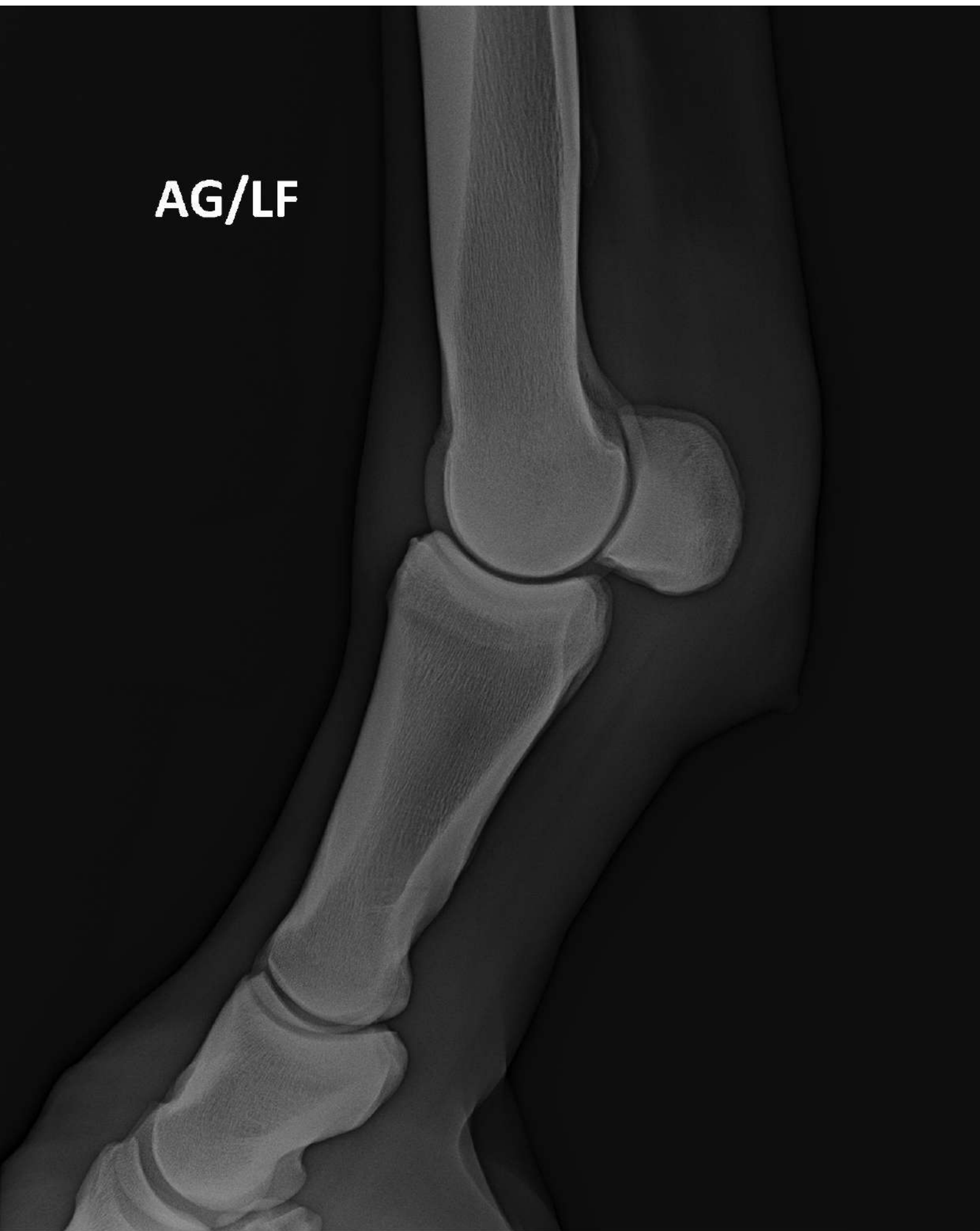
10/24/2024
SELARL EQUISYN

AG/LF

LIMALAYA DE RIVERLAND
SCEA RIVERLAND

10/24/2024
SELARL EQUISYN

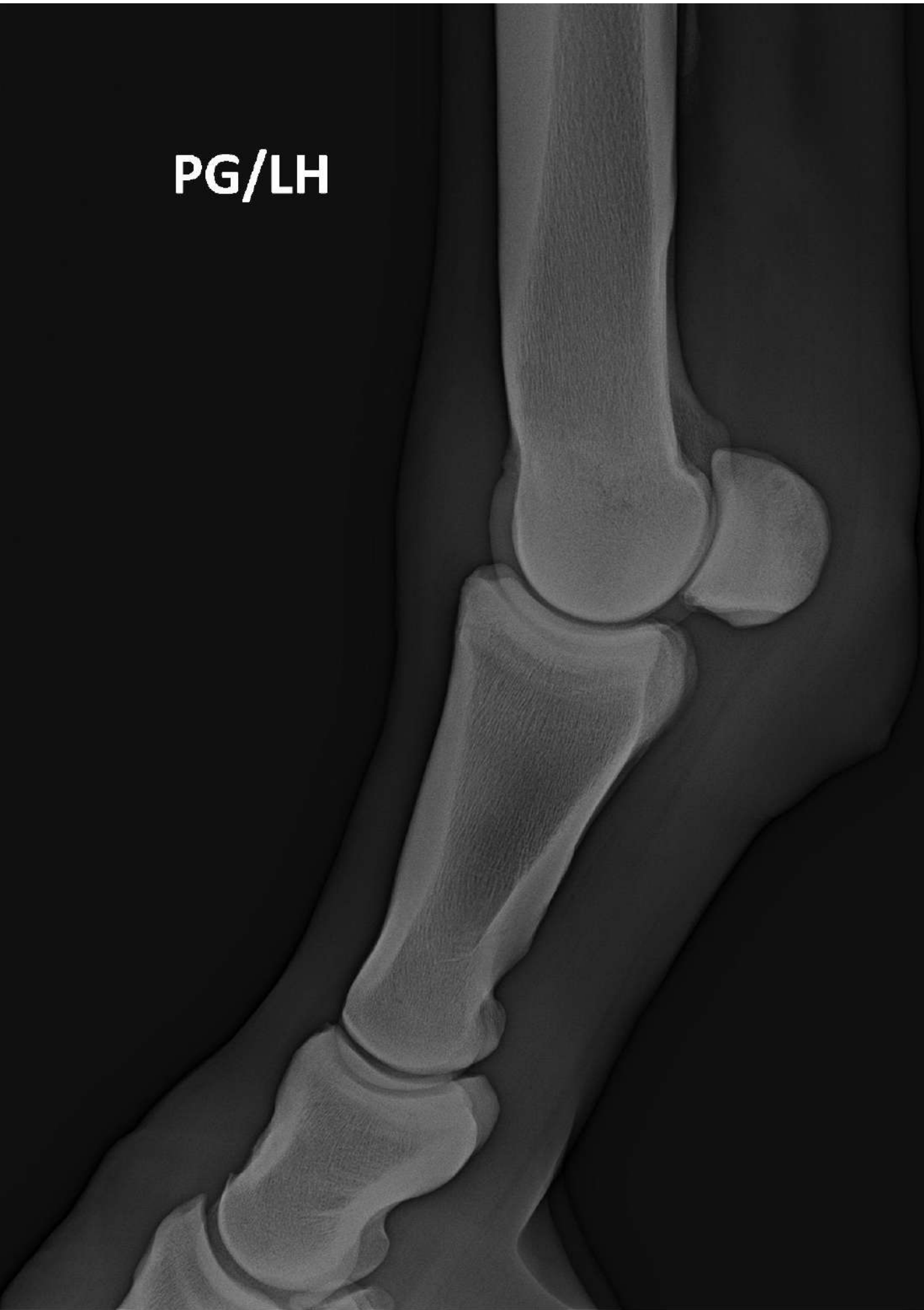AG/LF

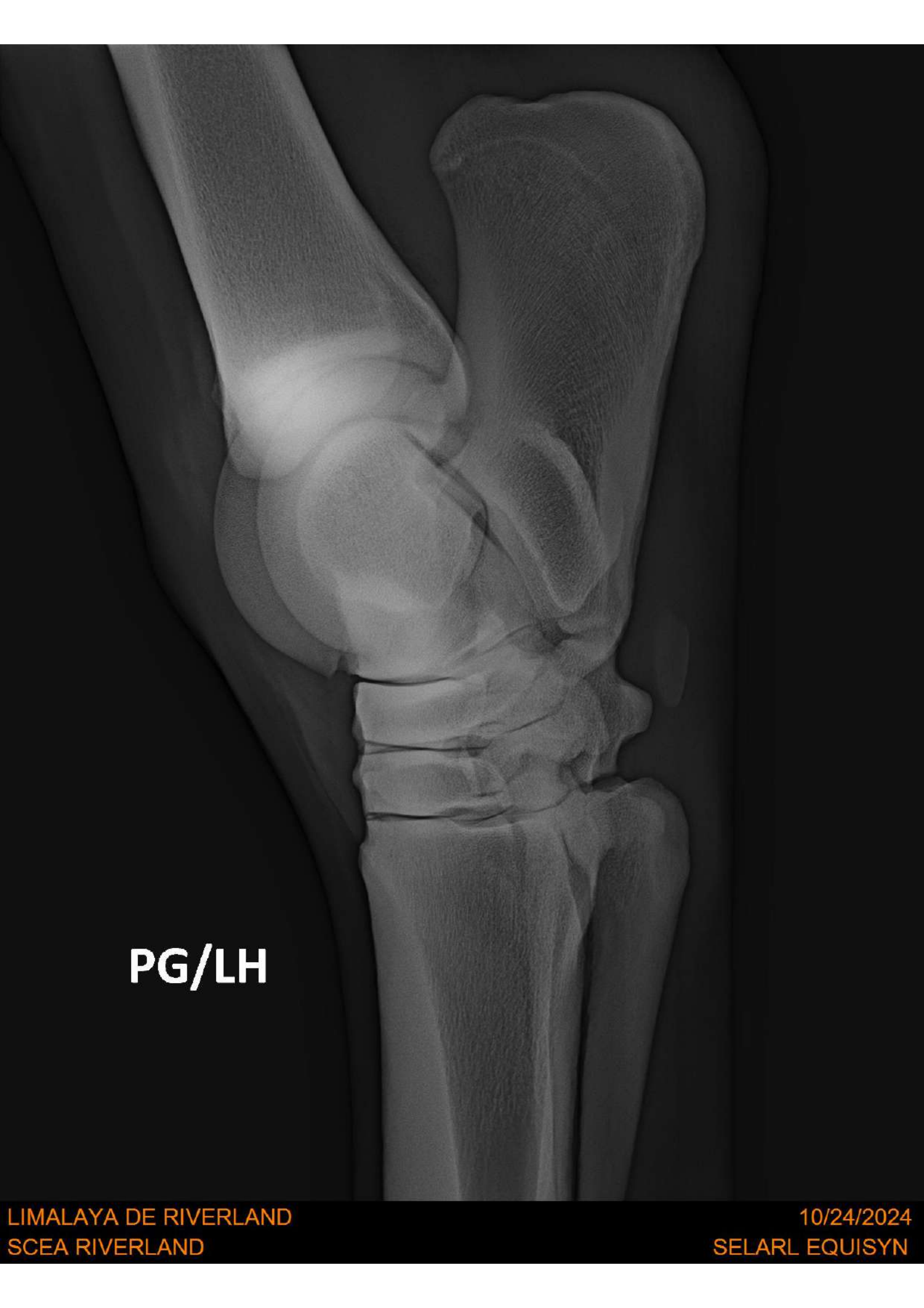


An anteroposterior (AP) radiograph of a horse's knee joint. The image shows the distal femur at the top, the patella in the middle, and the proximal tibia at the bottom. The joint space is clearly visible, and the bones appear well-aligned. The text 'AG/LF' is printed in the upper right corner of the image.

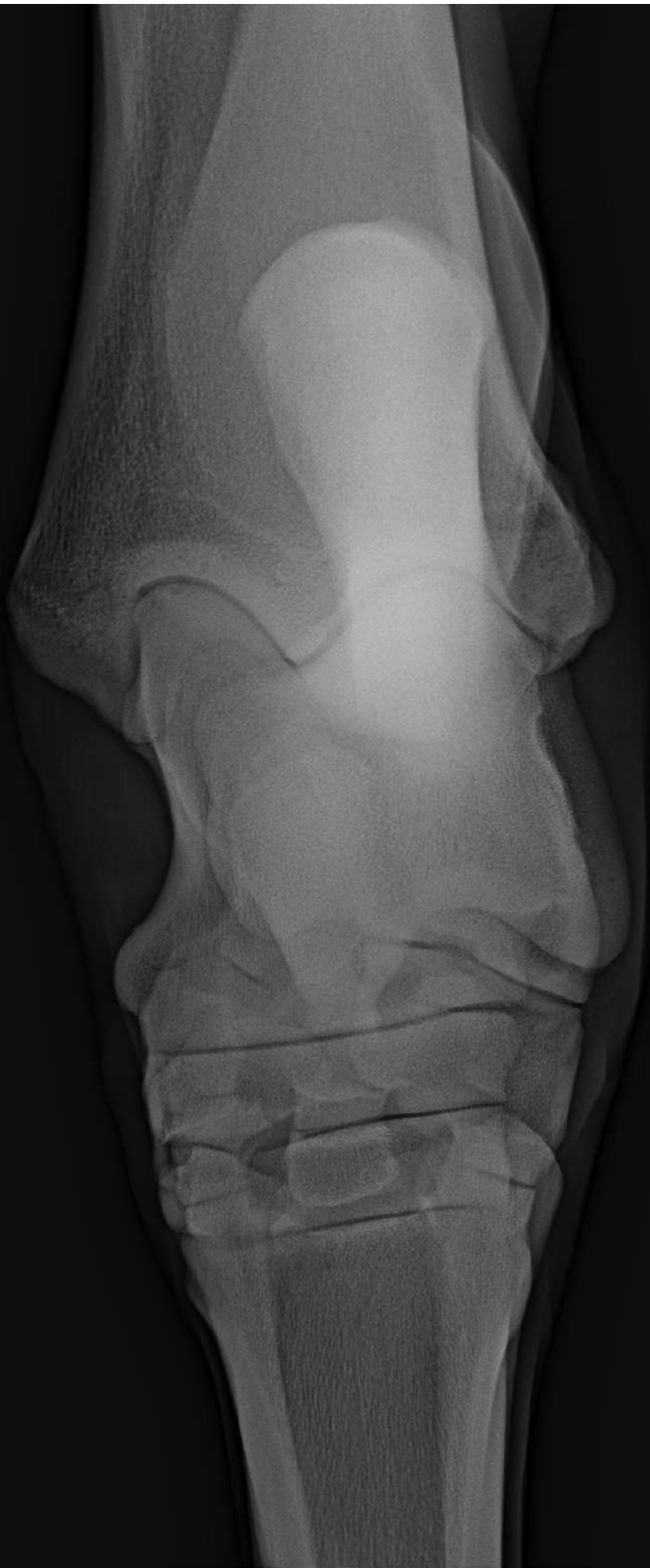AG/LF

PG/LH



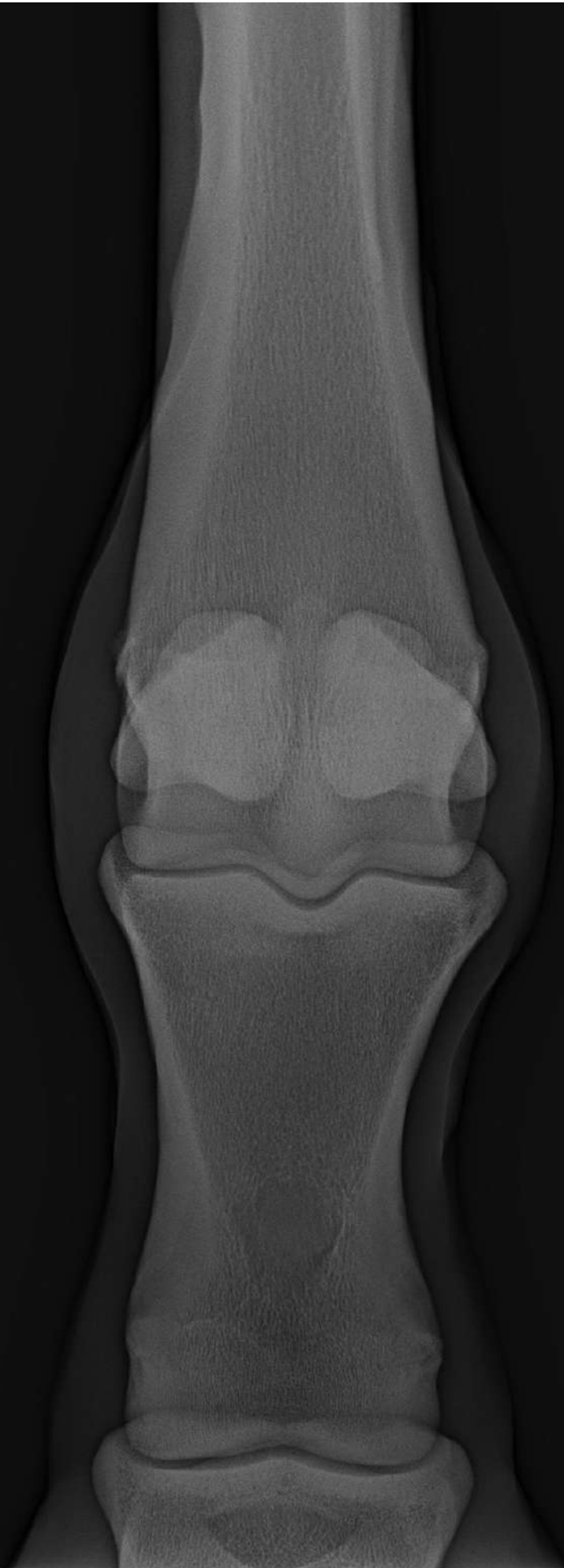

PG/LH



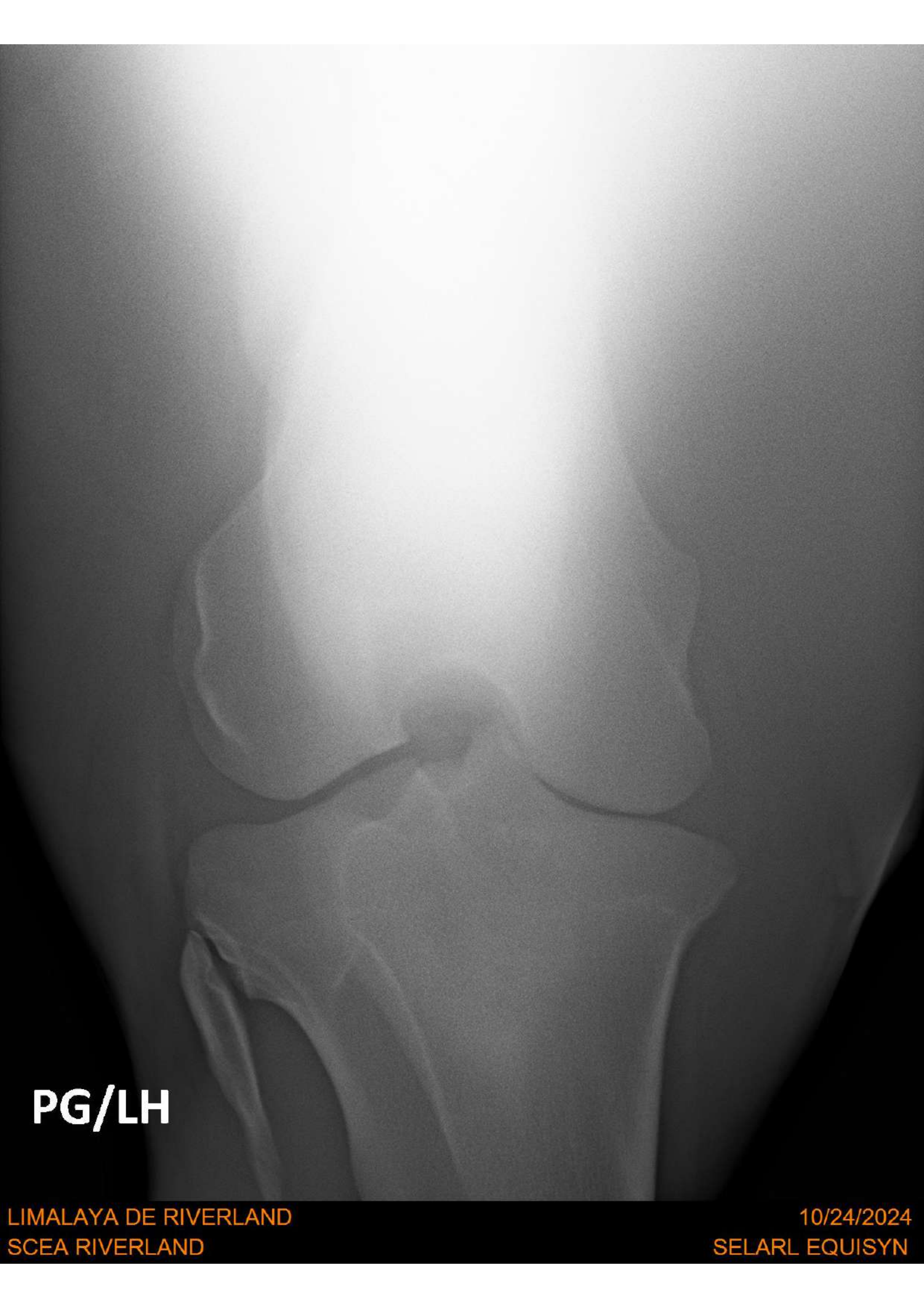
PG/LH

PG/LH

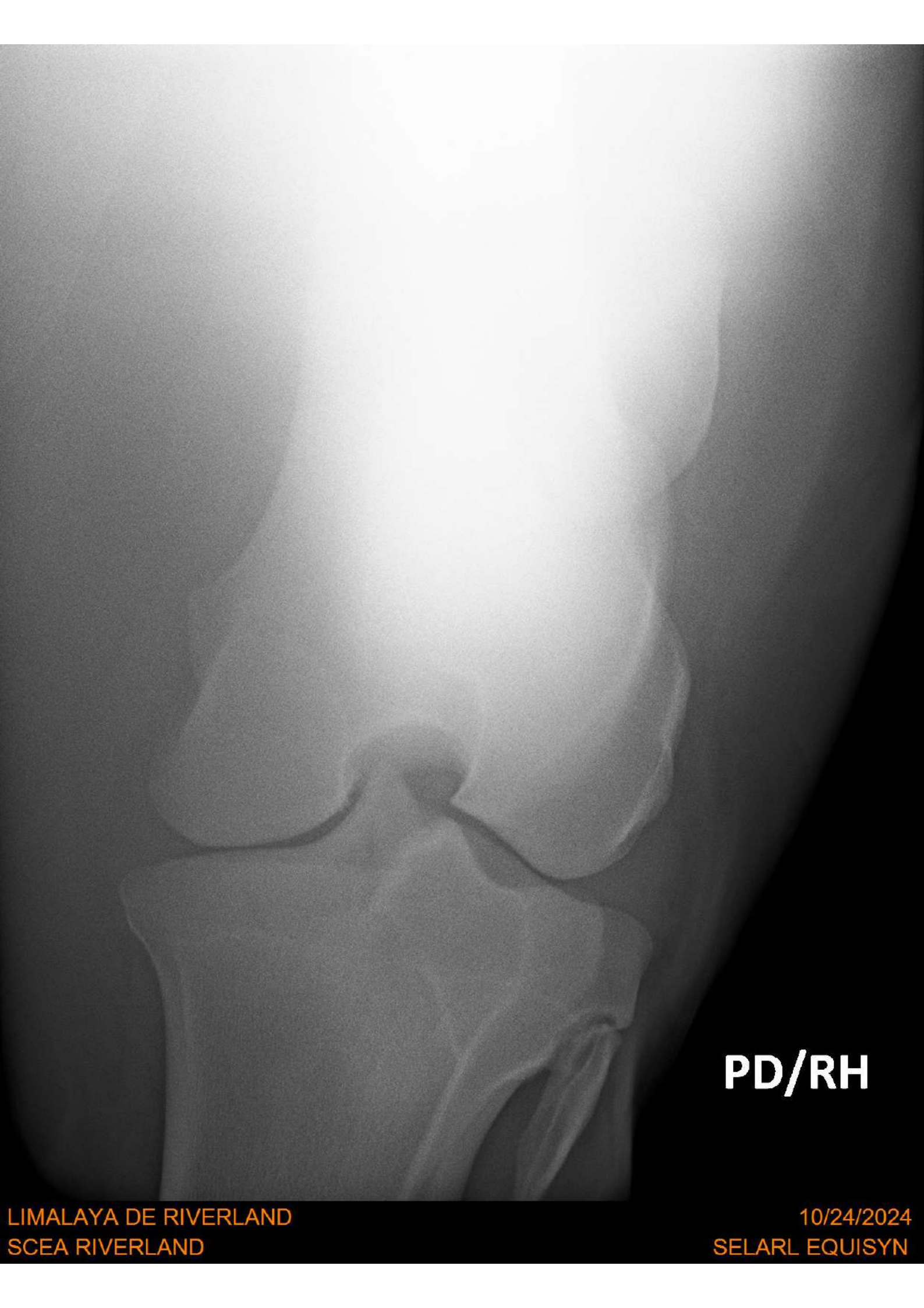




PG/LH



PG/LH



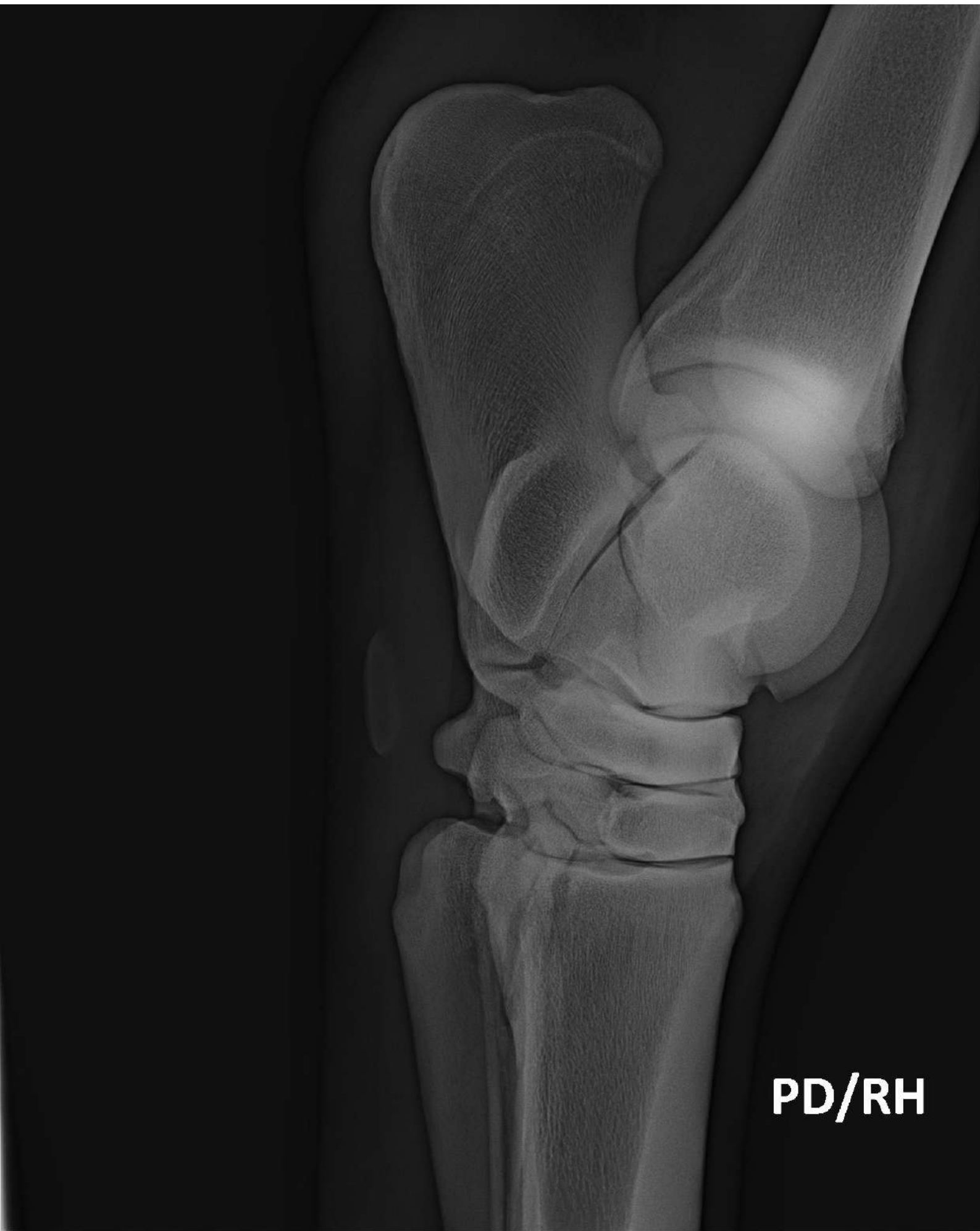PD/RH

LIMALAYA DE RIVERLAND
SCEA RIVERLAND

10/24/2024
SELARL EQUISYN

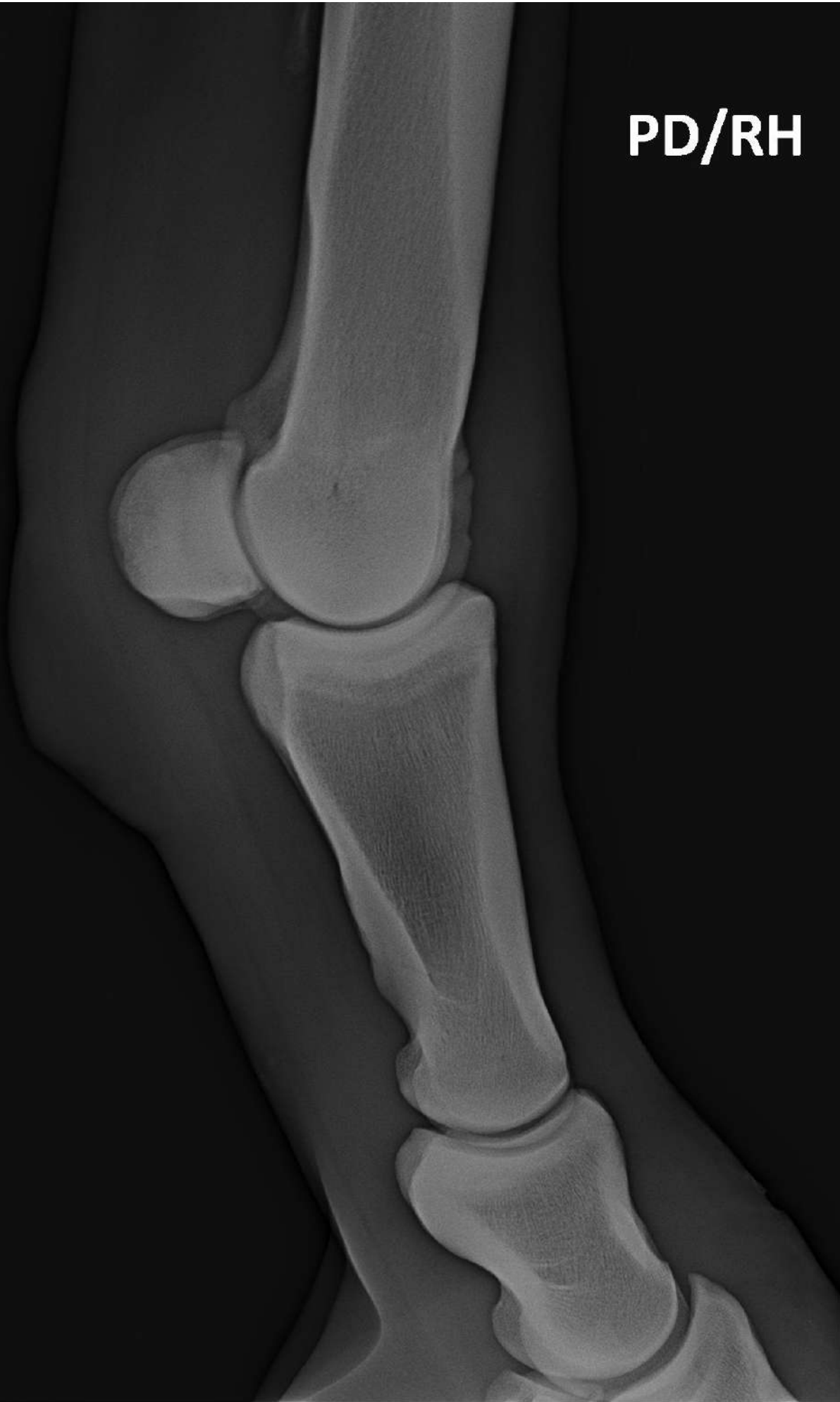

PD/RH

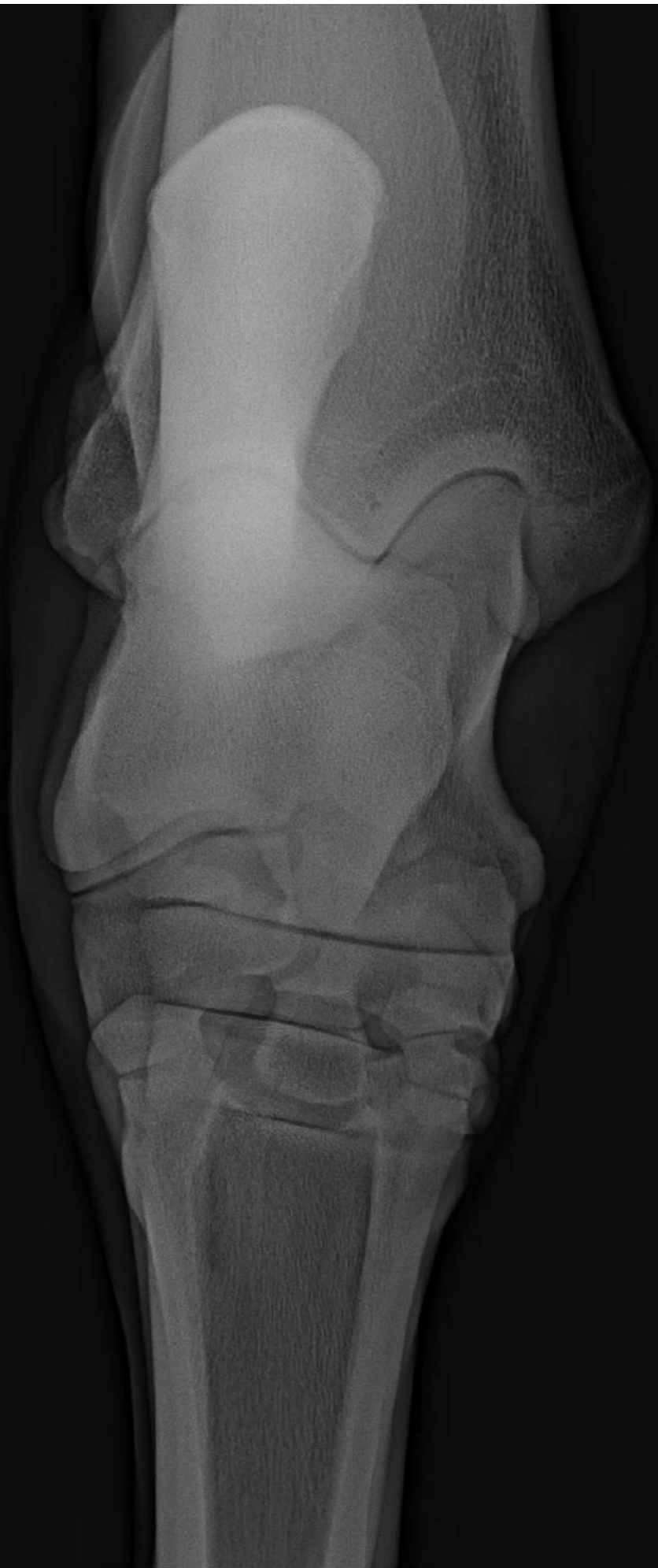

PD/RH

PD/RH

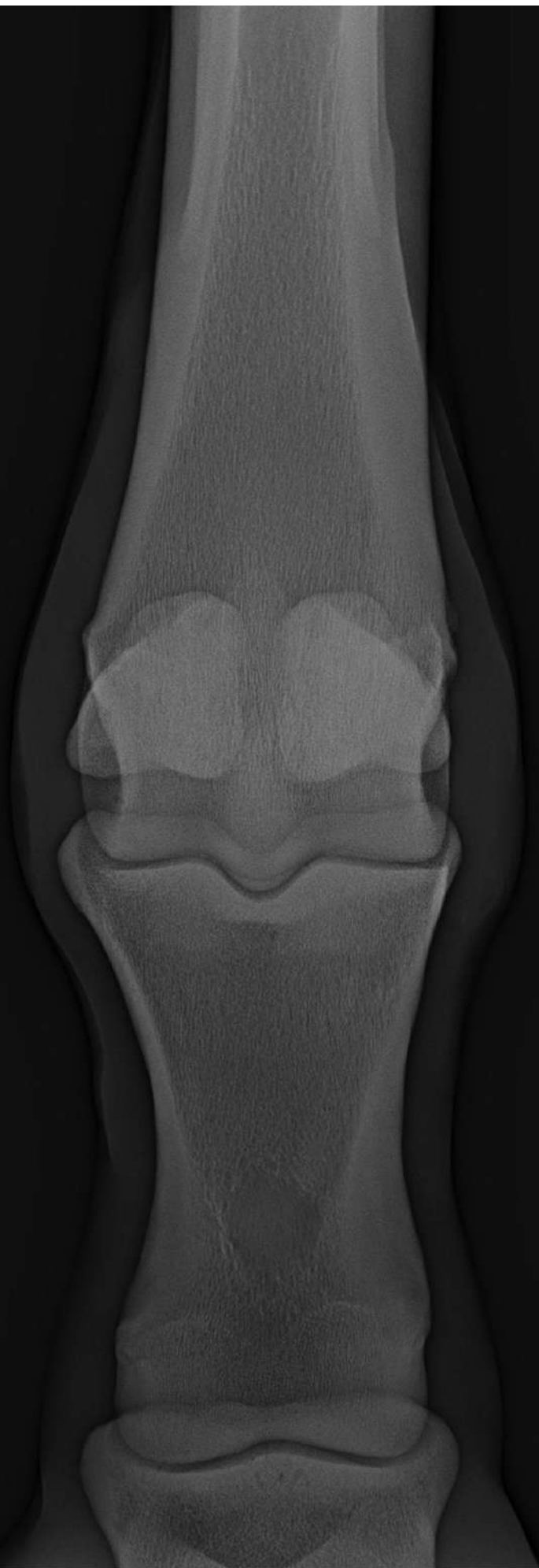

AD/RF

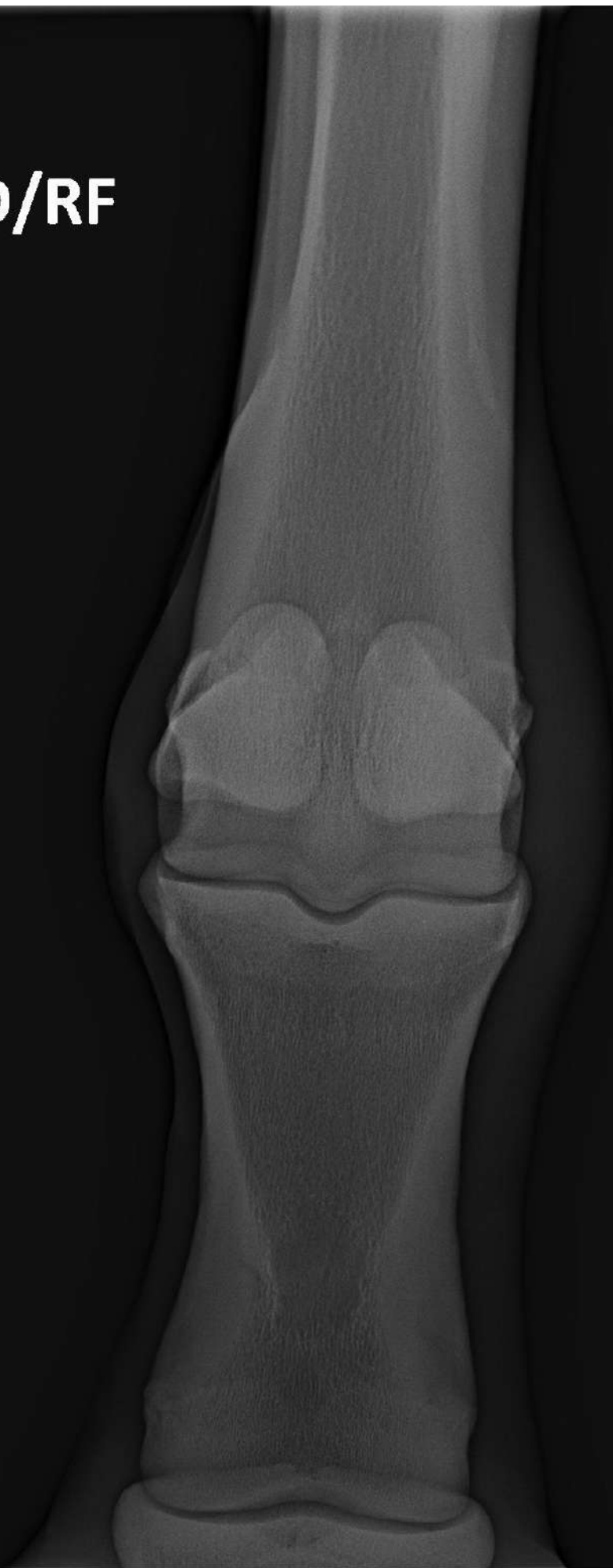

PD/RH

PD/RH



AD/RF

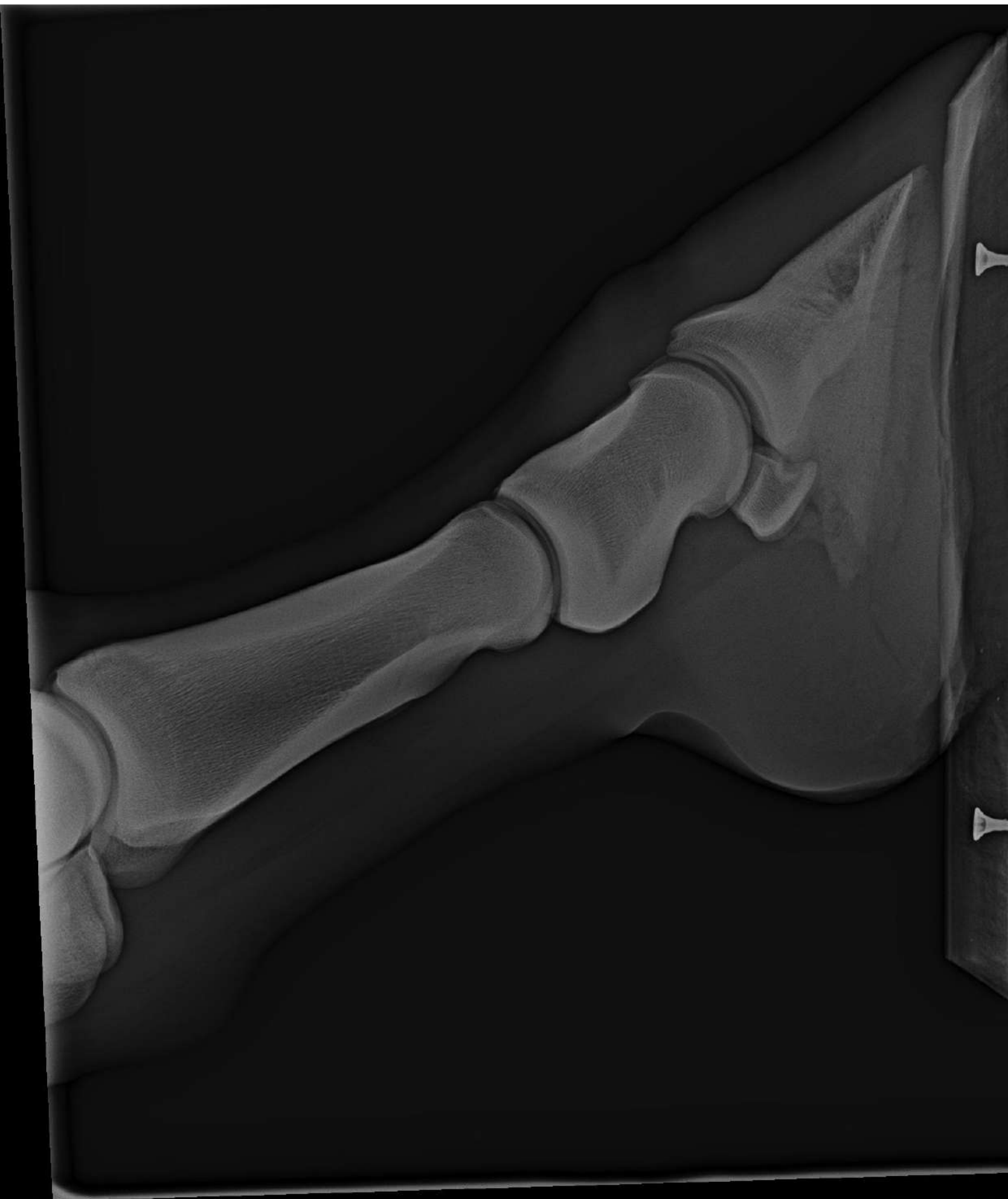


AD/RF



LIMALAYA DE RIVERLAND
SCEA RIVERLAND

10/24/2024
SELARL EQUISYN



LIMALAYA DE RIVERLAND
SCEA RIVERLAND

10/24/2024
SELARL EQUISYN