

Clinique VETBRIERE
Img: 1
Anatomy: Boulet
View: Latéral
Lat: AD

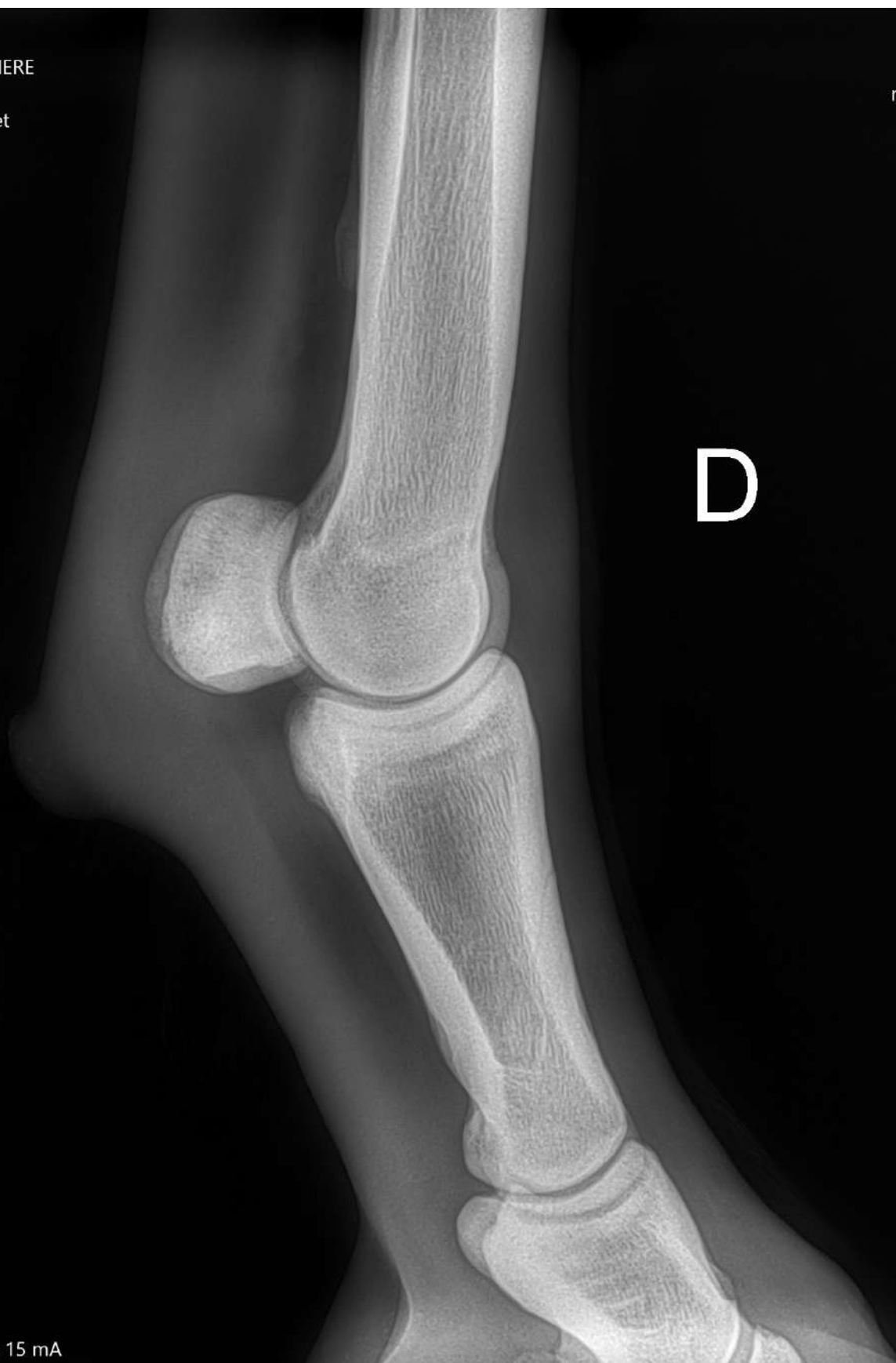
Vet Rec:
rozzonelli, lucky onchao
Cheval
Acq Dt: 15/11/2024
Acq Tm: 11:42

AD

D

76 kVp 1,6 mAs 15 mA

DX

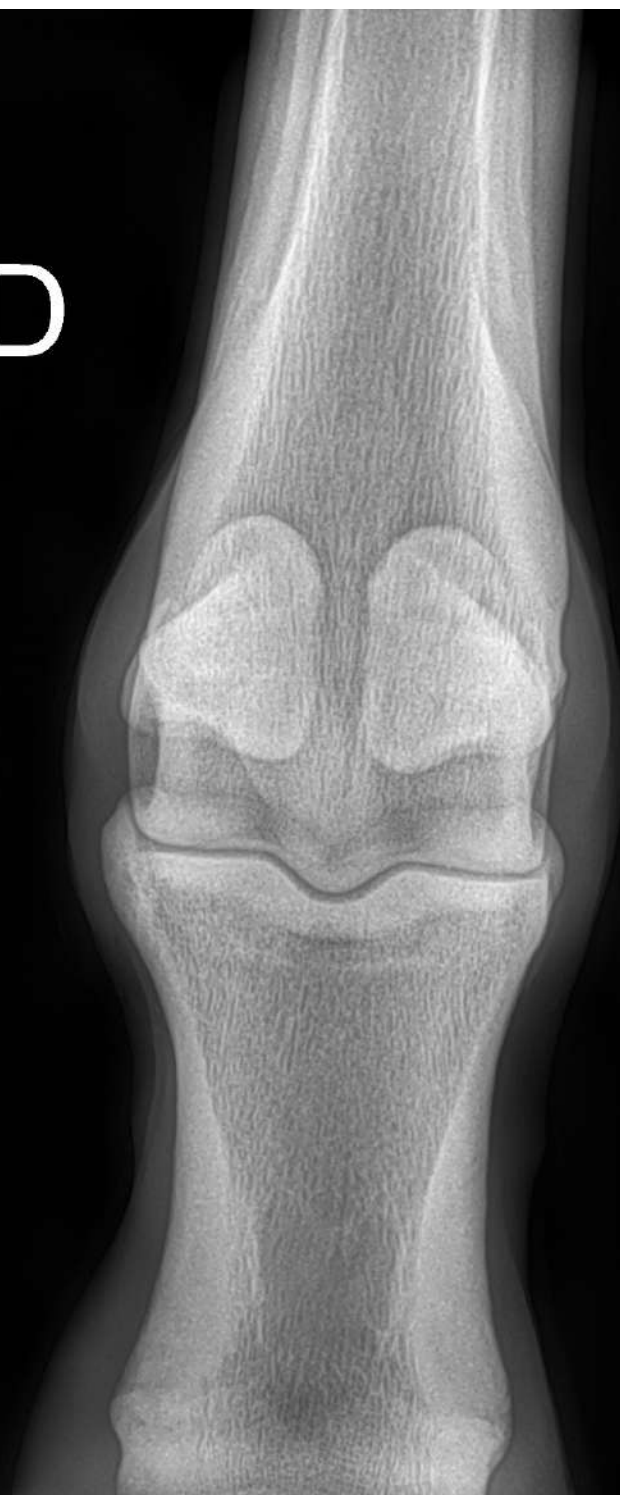

Clinique VETBRIERE
Img: 2
Anatomy: Boulet
View: Latéral
Lat: AD

Vet Rec:
rozzonelli, lucky onchao
Cheval
Acq Dt: 15/11/2024
Acq Tm: 11:42

D

AD



76 kVp 1,6 mAs 15 mA

DX

Clinique VETBRIERE
Img: 3
Anatomy: Boulet
View: Latéral
Lat: AG

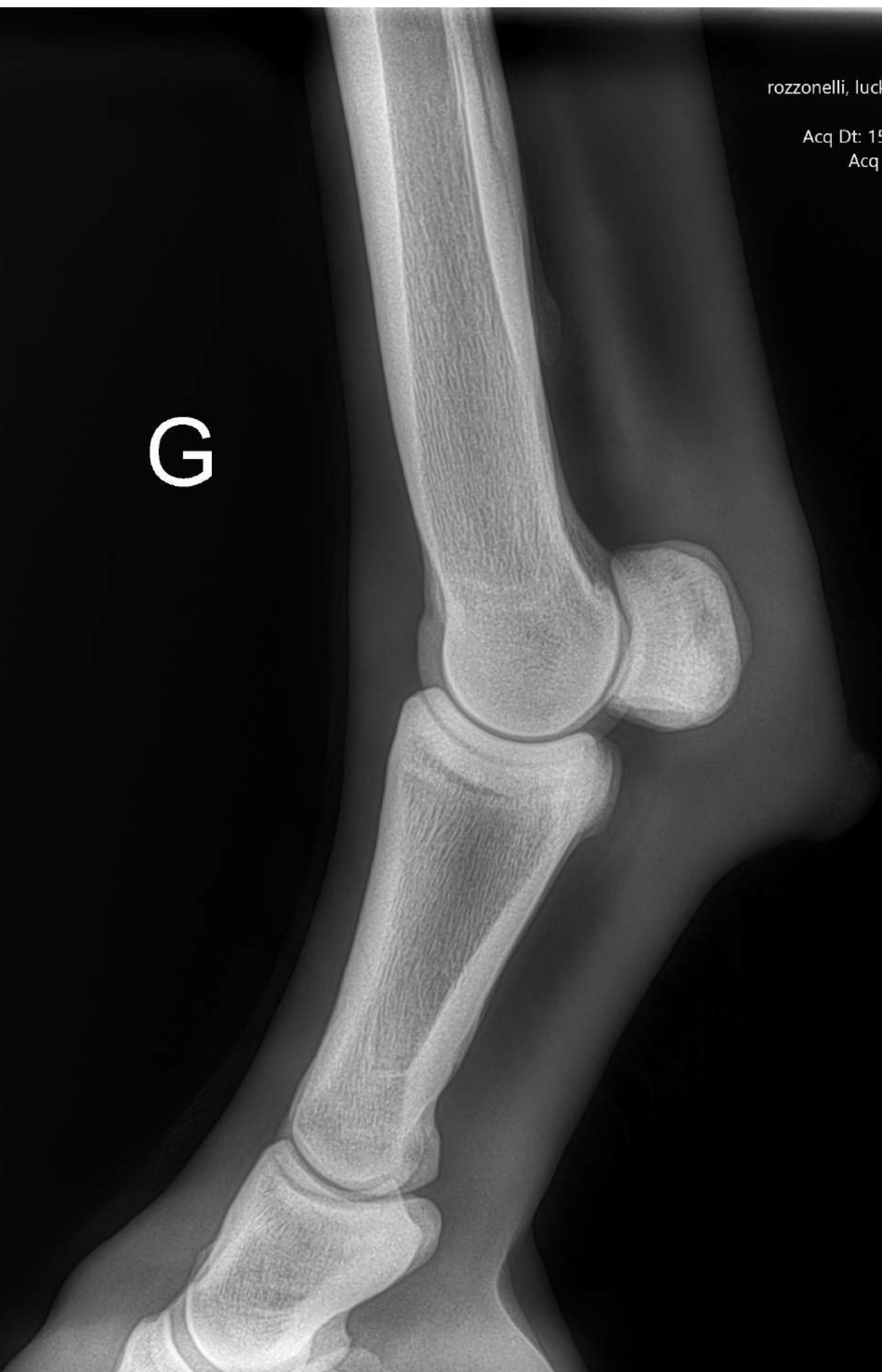Vet Rec:
rozzonelli, lucky onchao
Cheval
Acq Dt: 15/11/2024
Acq Tm: 11:43

AG

G

76 kVp 1,6 mAs 15 mA

DX



Clinique VETBRIERE
Img: 4
Anatomy: Boulet
View: DP
Lat: AG

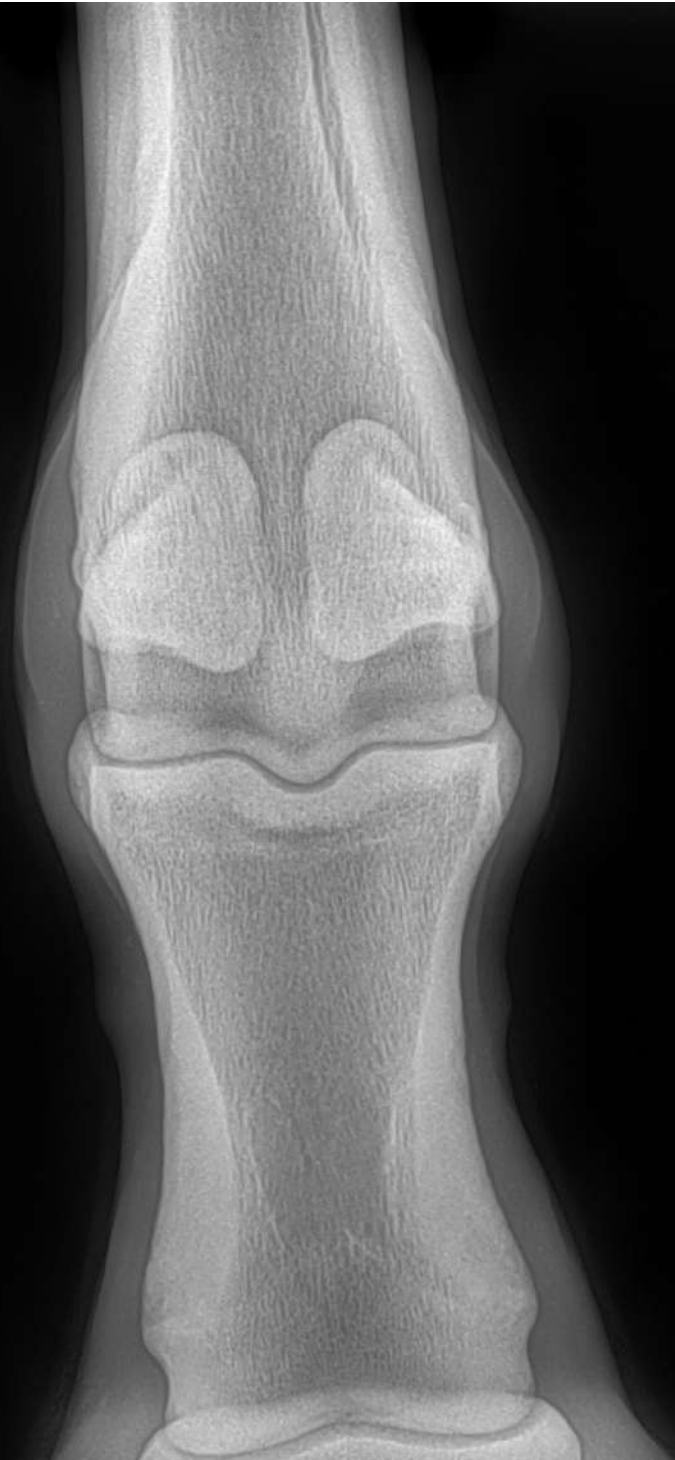
Vet Rec:
rozzonelli, lucky onchao
Cheval
Acq Dt: 15/11/2024
Acq Tm: 11:43

G

AG

76 kVp 1,6 mAs 15 mA

DX



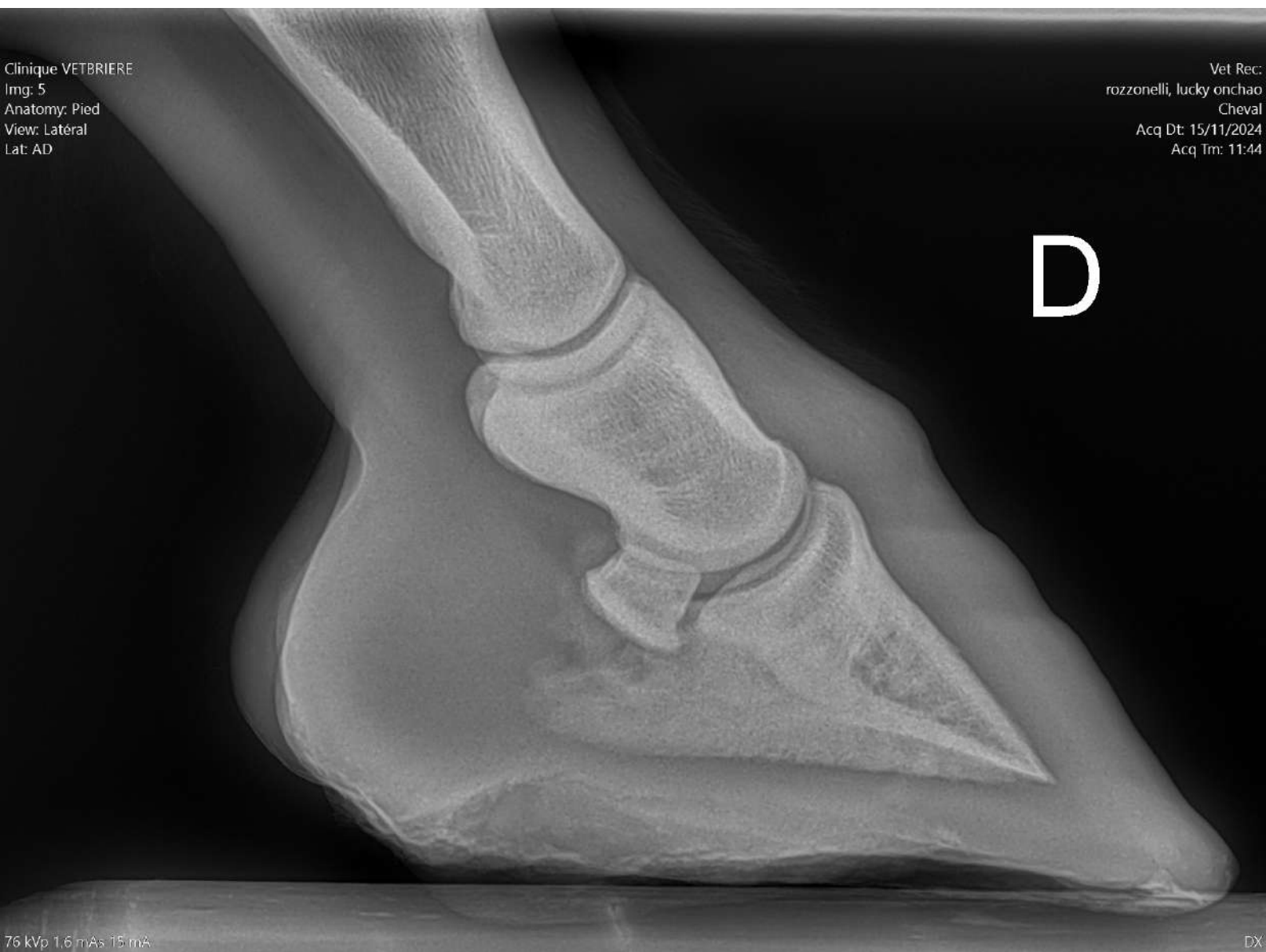Clinique VETBRIERE
Img: 5
Anatomy: Pied
View: Latéral
Lat: AD

Vet Rec:
rozzonelli, lucky onchao
Cheval
Acq Dt: 15/11/2024
Acq Tm: 11:44

D

76 kVp 1,6 mAs 15 mA

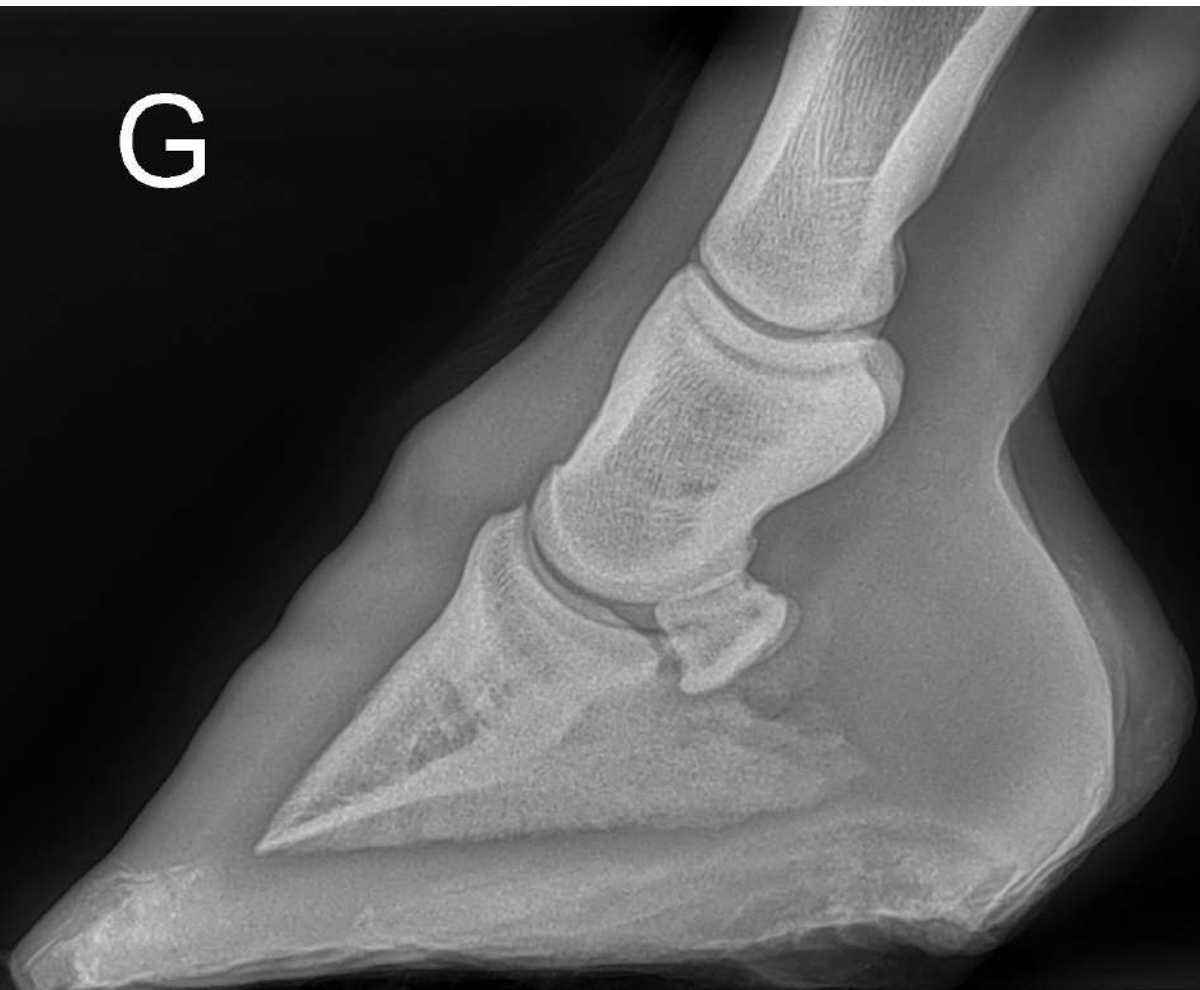
DX



Clinique VETBRIERE
Img: 6
Anatomy: Pied
View: Latéral
Lat: AG

G

Vet Rec:
rozzonelli, lucky onchao
Cheval
Acq Dt: 15/11/2024
Acq Tm: 11:45



76 kVp 1,6 mAs 15 mA

DX

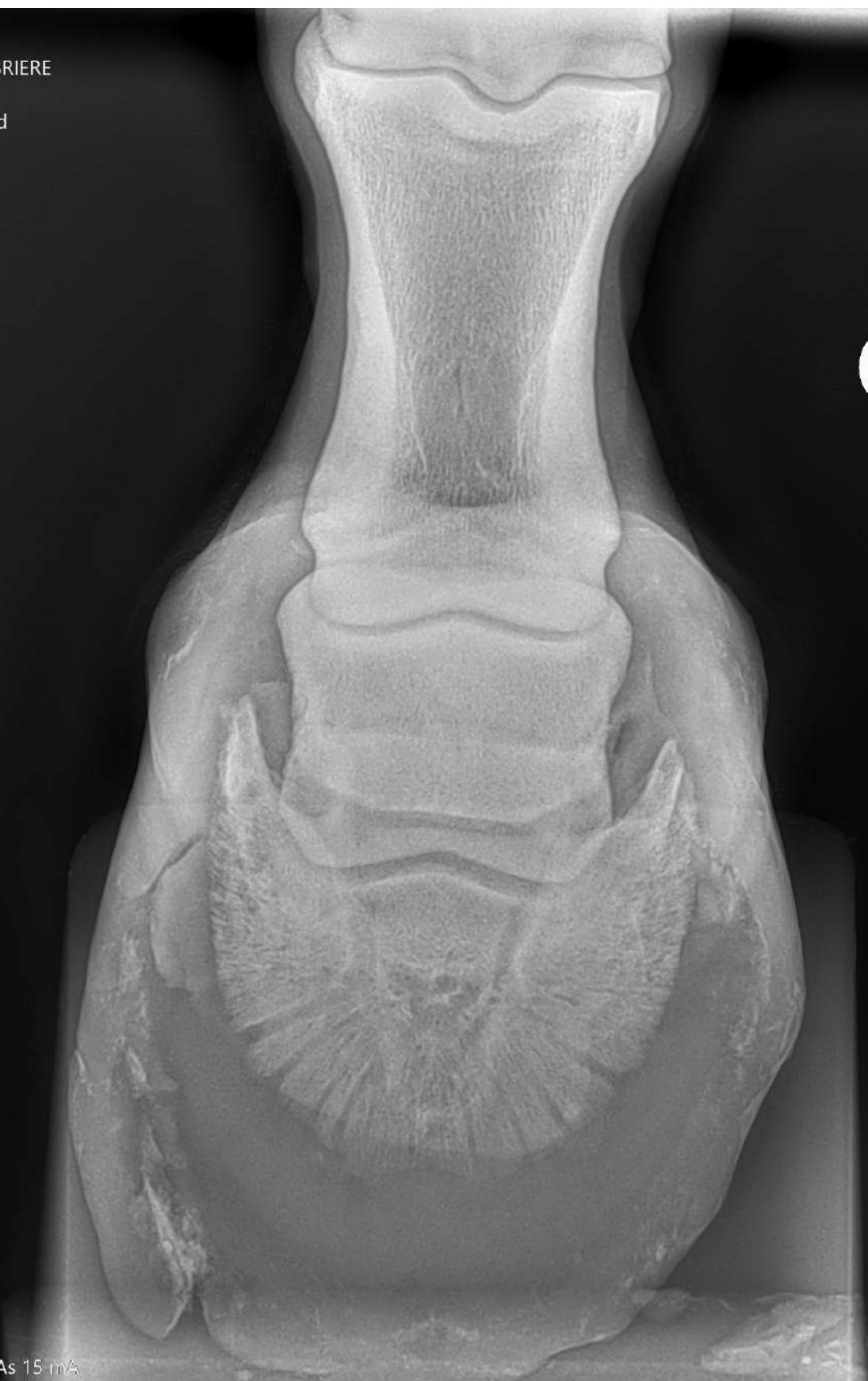Clinique VETBRIERE
Img: 7
Anatomy: Pied
View: DP
Lat: AG

Vet Rec:
rozzonelli, lucky onchao
Cheval
Acq Dt: 15/11/2024
Acq Tm: 11:47

G

76 kVp 1,6 mAs 15 mA

DX



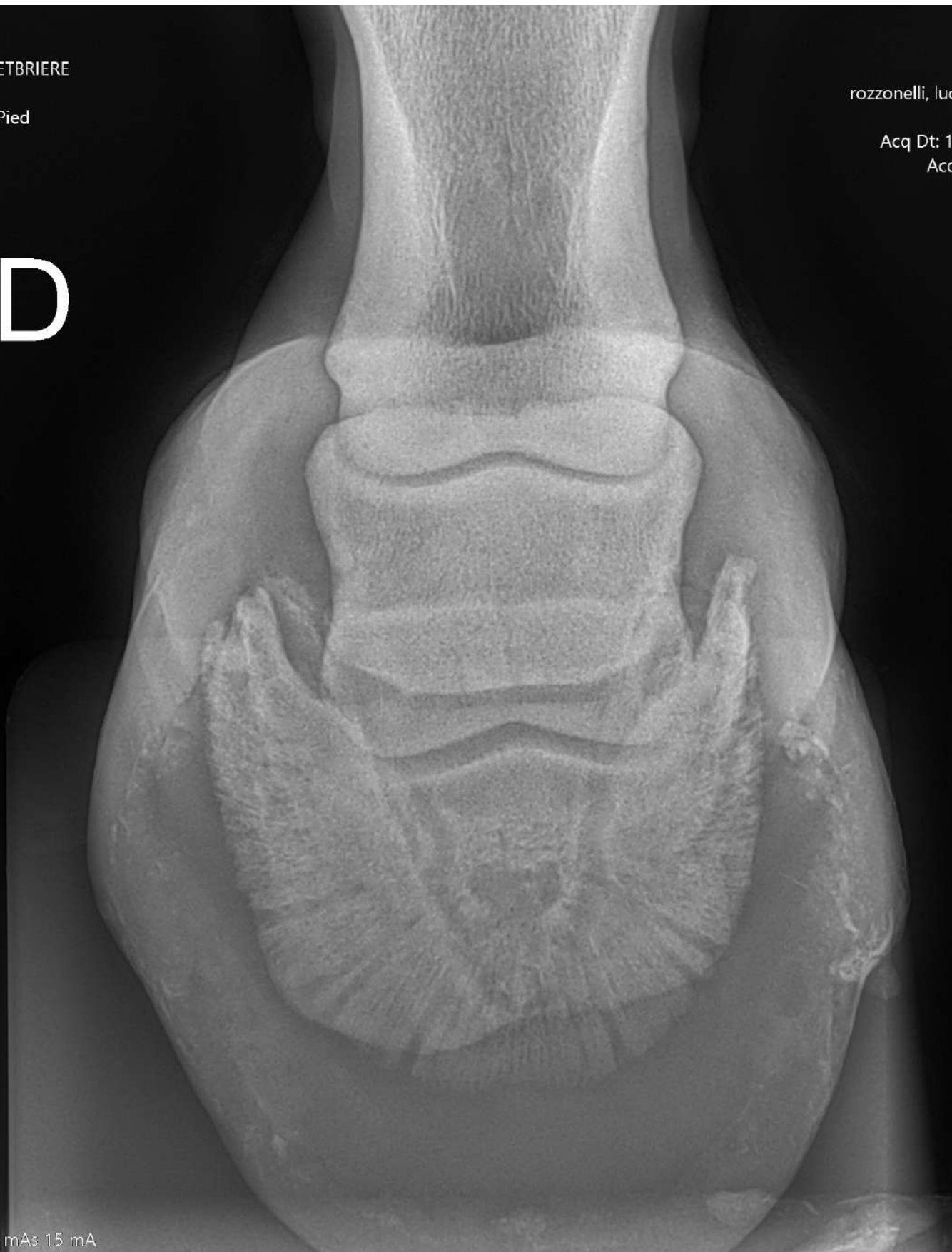Clinique VETBRIERE
Img: 8
Anatomy: Pied
View: DP
Lat: AG

Vet Rec:
rozzonelli, lucky onchao
Cheval
Acq Dt: 15/11/2024
Acq Tm: 11:48

D

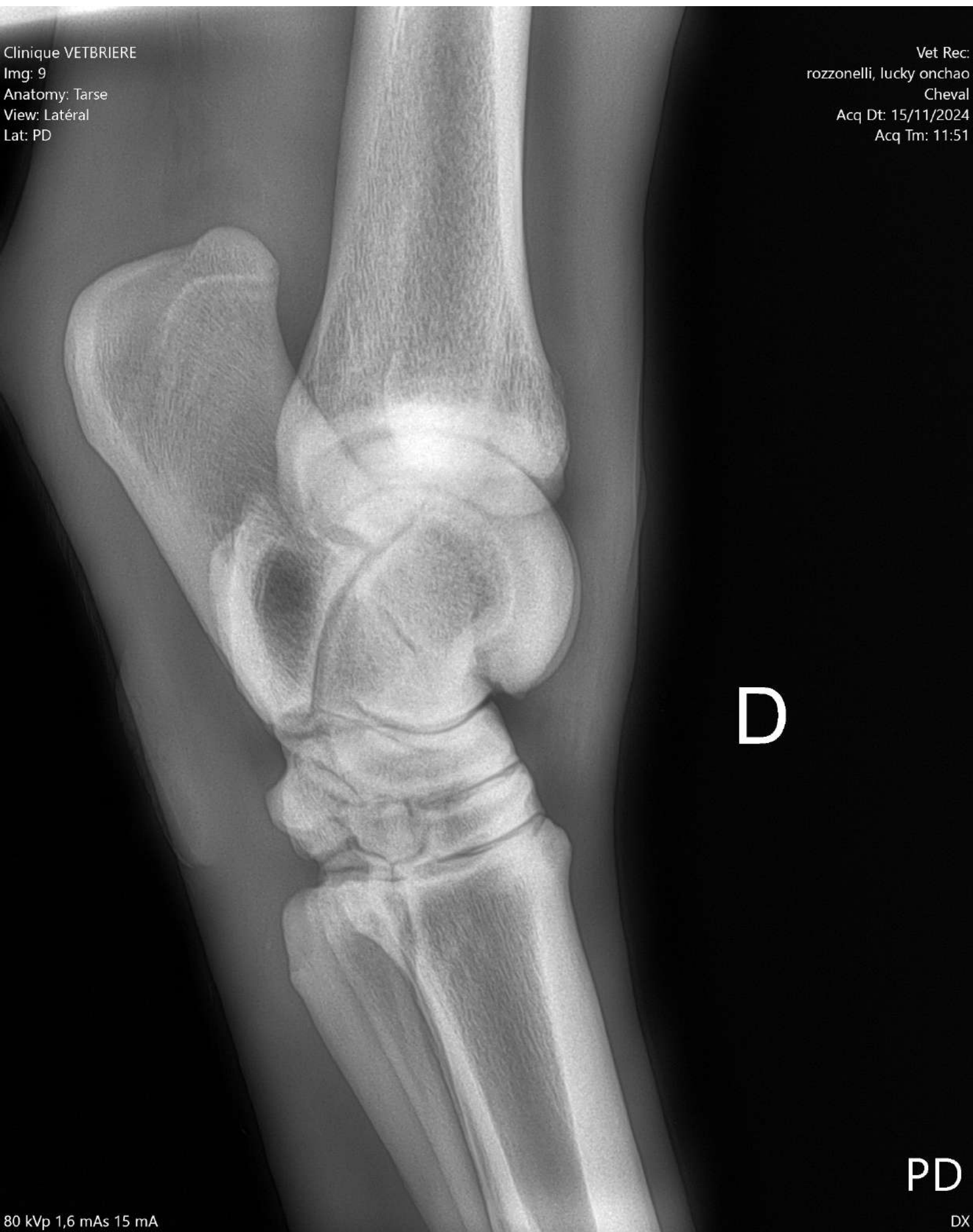
76 kVp 1.6 mAs 1.5 mA

DX



Clinique VETBRIERE
Img: 9
Anatomy: Tarse
View: Latéral
Lat: PD

Vet Rec:
rozzonelli, lucky onchao
Cheval
Acq Dt: 15/11/2024
Acq Tm: 11:51



D

PD

80 kVp 1,6 mAs 15 mA

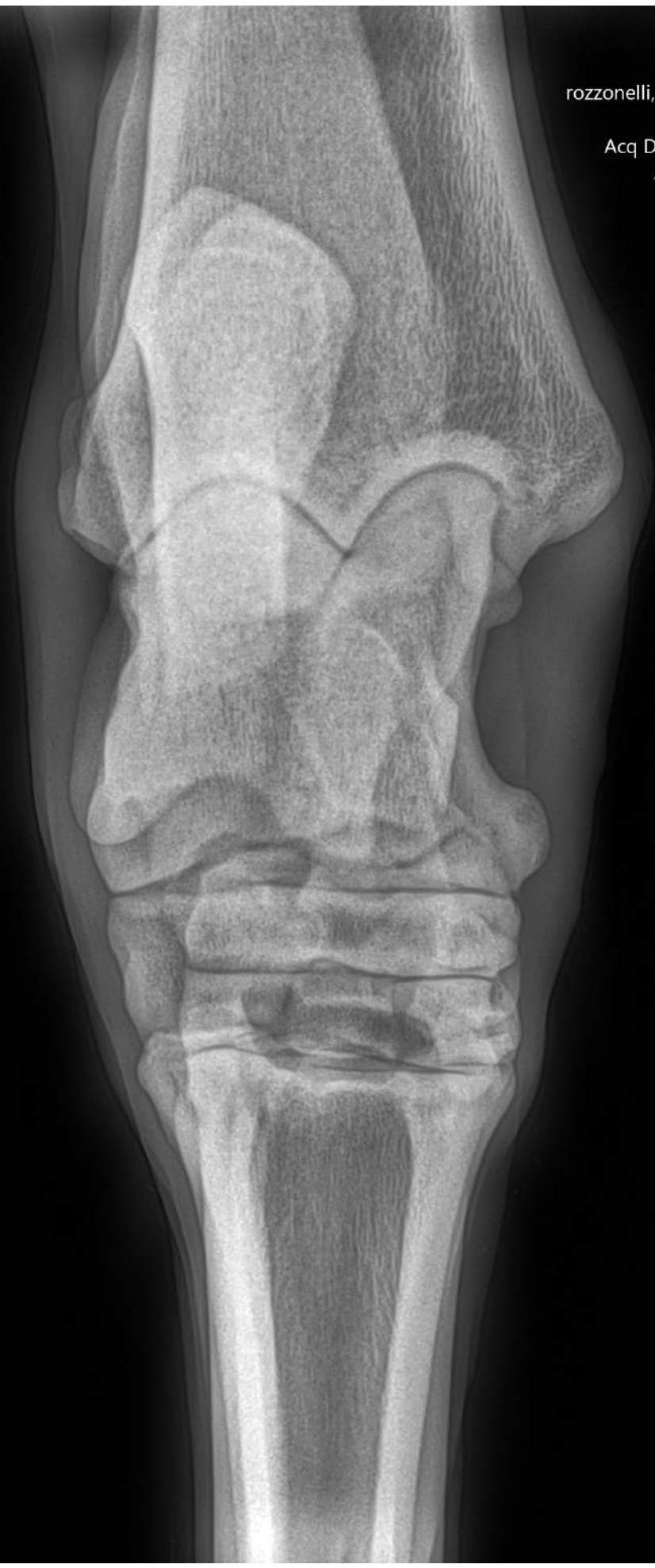DX

Clinique VETBRIERE
Img: 10
Anatomy: Tarse
View: DP
Lat: PD

Vet Rec:
rozzonelli, lucky onchao
Cheval
Acq Dt: 15/11/2024
Acq Tm: 11:52

PD

D



Clinique VETBRIERE
Img: 11
Anatomy: Boulet
View: Latéral
Lat: PD

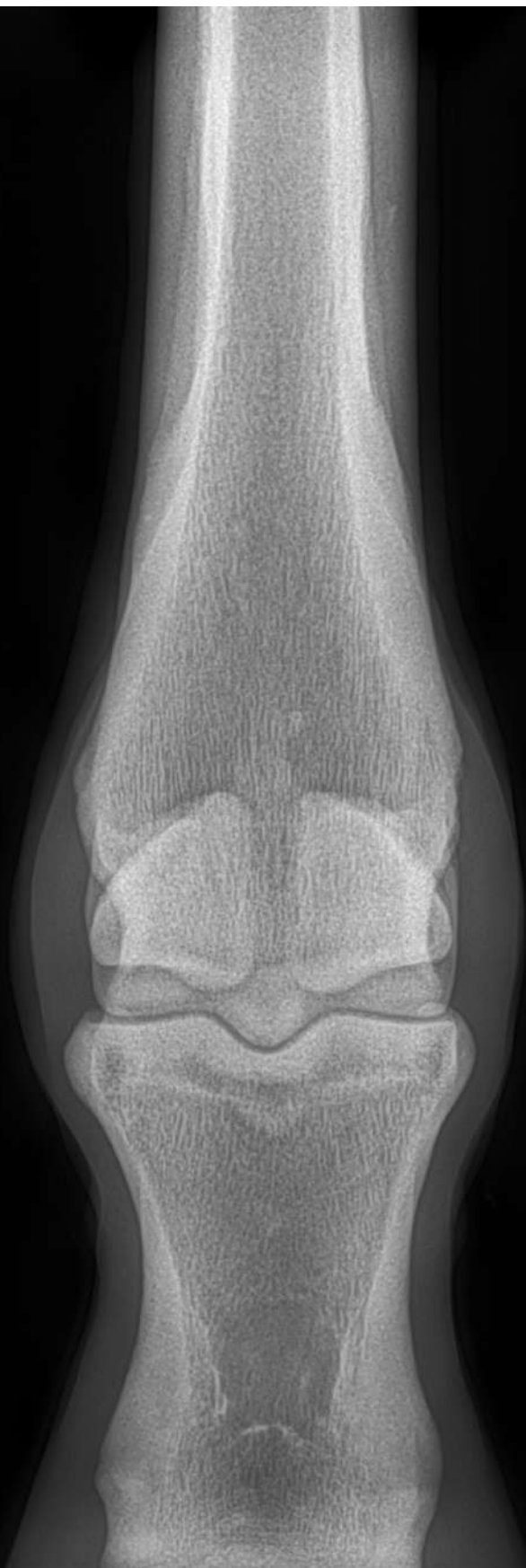Vet Rec:
rozzonelli, lucky onchao
Cheval
Acq Dt: 15/11/2024
Acq Tm: 11:53

PD

D

76 kVp 1,6 mAs 15 mA

DX



Clinique VETBRIERE
Img: 12
Anatomy: Boulet
View: Latéral
Lat: PD

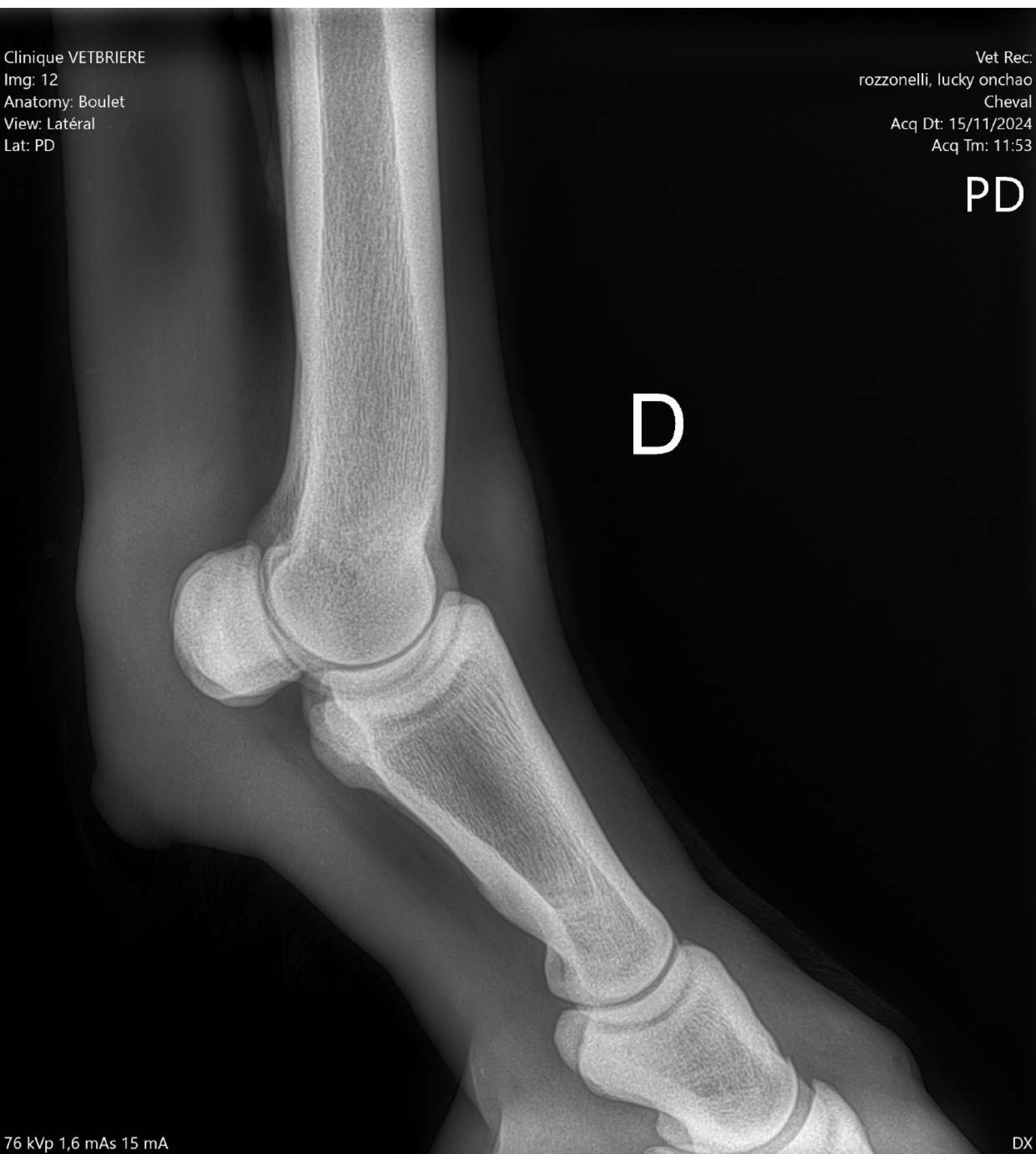
Vet Rec:
rozzonelli, lucky onchao
Cheval
Acq Dt: 15/11/2024
Acq Tm: 11:53

PD

D

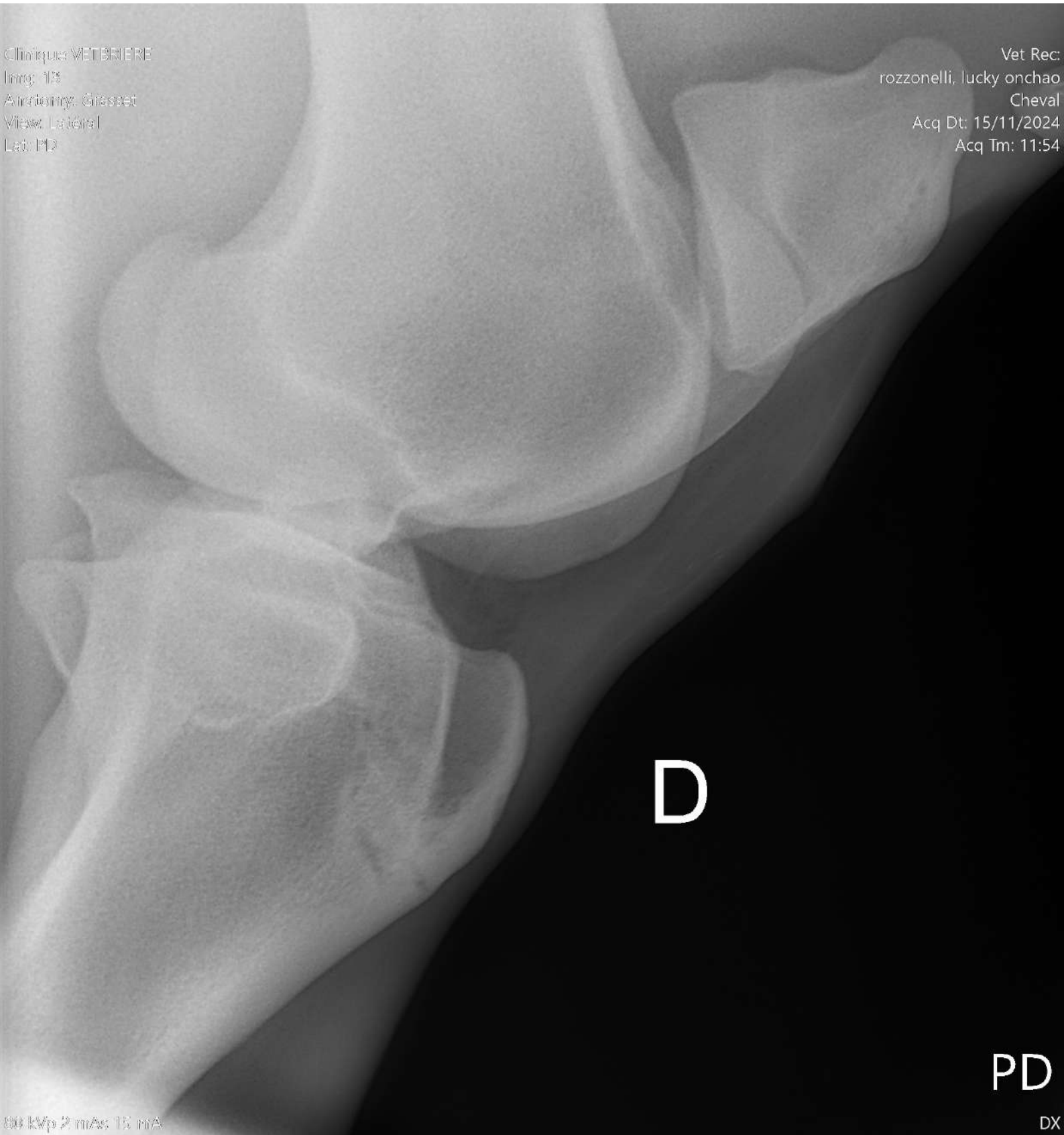
76 kVp 1,6 mAs 15 mA

DX



Clinique VETBRIERE
Imag: 13
Anatomy: Gresset
View: Latéral
Lat: PD

Vet Rec:
rozzonelli, lucky onchao
Cheval
Acq Dt: 15/11/2024
Acq Tm: 11:54



D

PD

80 kVp 2 mAs 15 mA

DX

Clinique VETBRIERE
Img: 14
Anatomy: Grasset
View: Caudo-crânial
Lat: PD

Vet Rec:
rozzonelli, lucky onchao
Cheval
Acq Dt: 15/11/2024
Acq Tm: 11:55

D

PD

90 kVp 5 mAs 15 mA

DX

Clinique VETBRIERE
Img: 15
Anatomy: Tarse
View: Latéral
Lat: PG

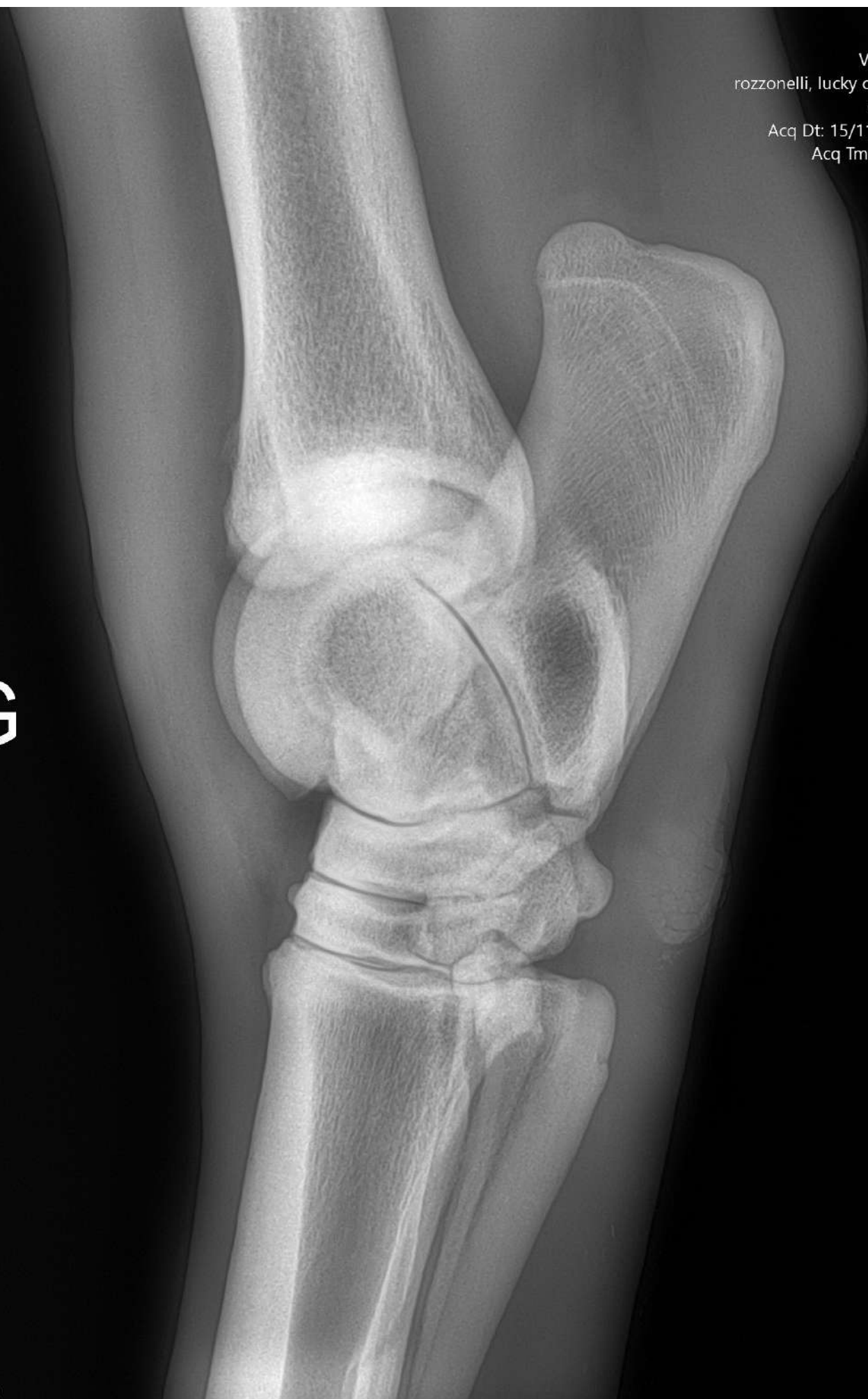
Vet Rec:
rozzonelli, lucky onchao
Cheval
Acq Dt: 15/11/2024
Acq Tm: 11:56

G

PG

80 kVp 1,6 mAs 15 mA

DX

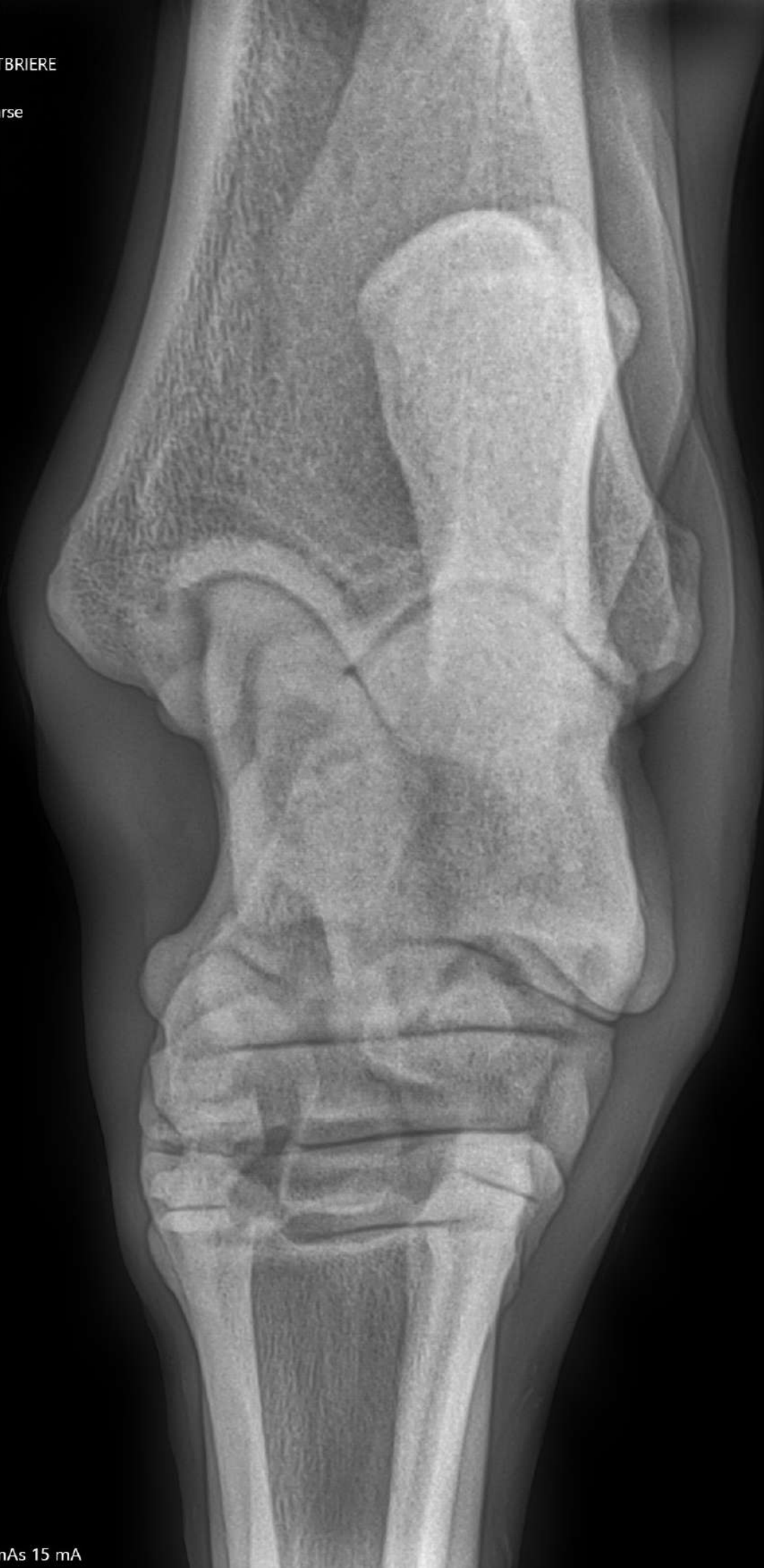

Clinique VETBRIERE
Img: 16
Anatomy: Tarse
View: DP
Lat: PG

Vet Rec:
rozzonelli, lucky onchao
Cheval
Acq Dt: 15/11/2024
Acq Tm: 12:01

PG

G



Clinique VETBRIERE
Img: 17
Anatomy: Boulet
View: Latéral
Lat: PG

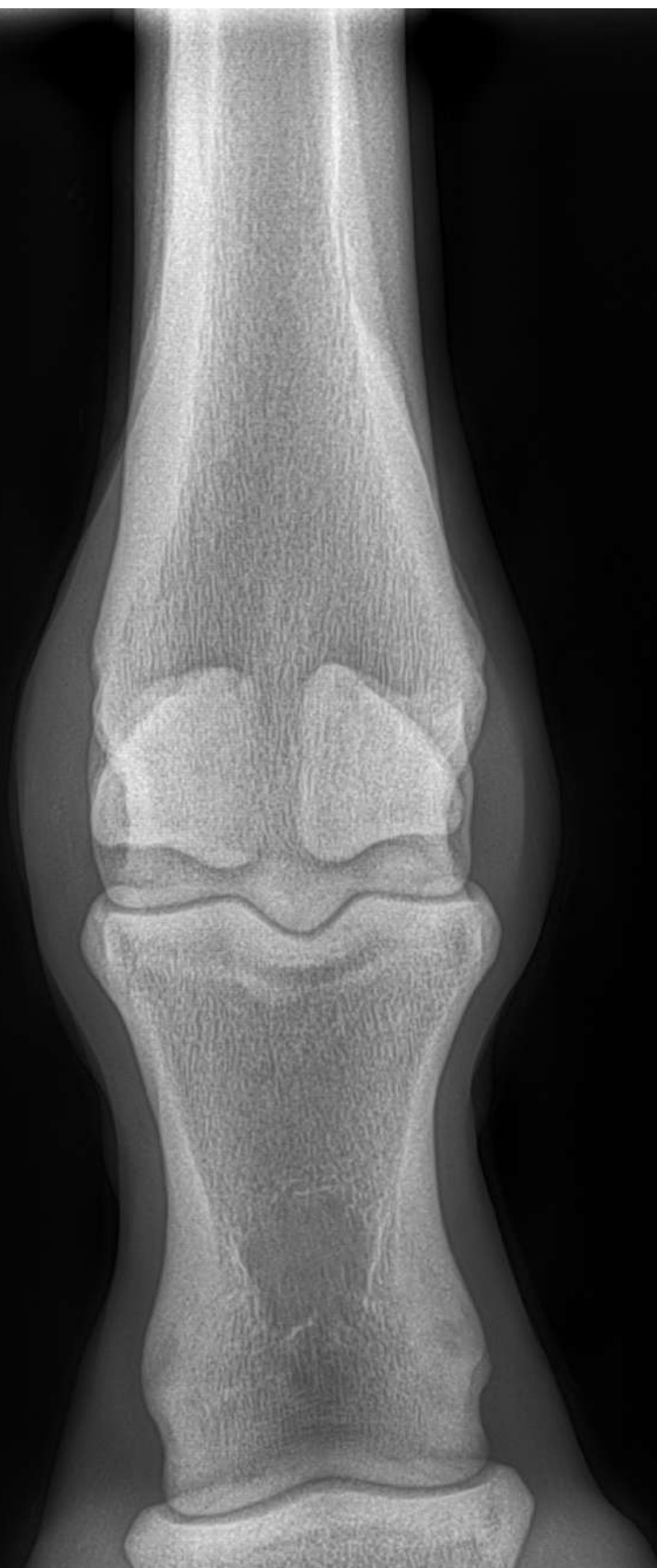Vet Rec:
rozzonelli, lucky onchao
Cheval
Acq Dt: 15/11/2024
Acq Tm: 12:02

PG

G

76 kVp 1,6 mAs 15 mA

DX

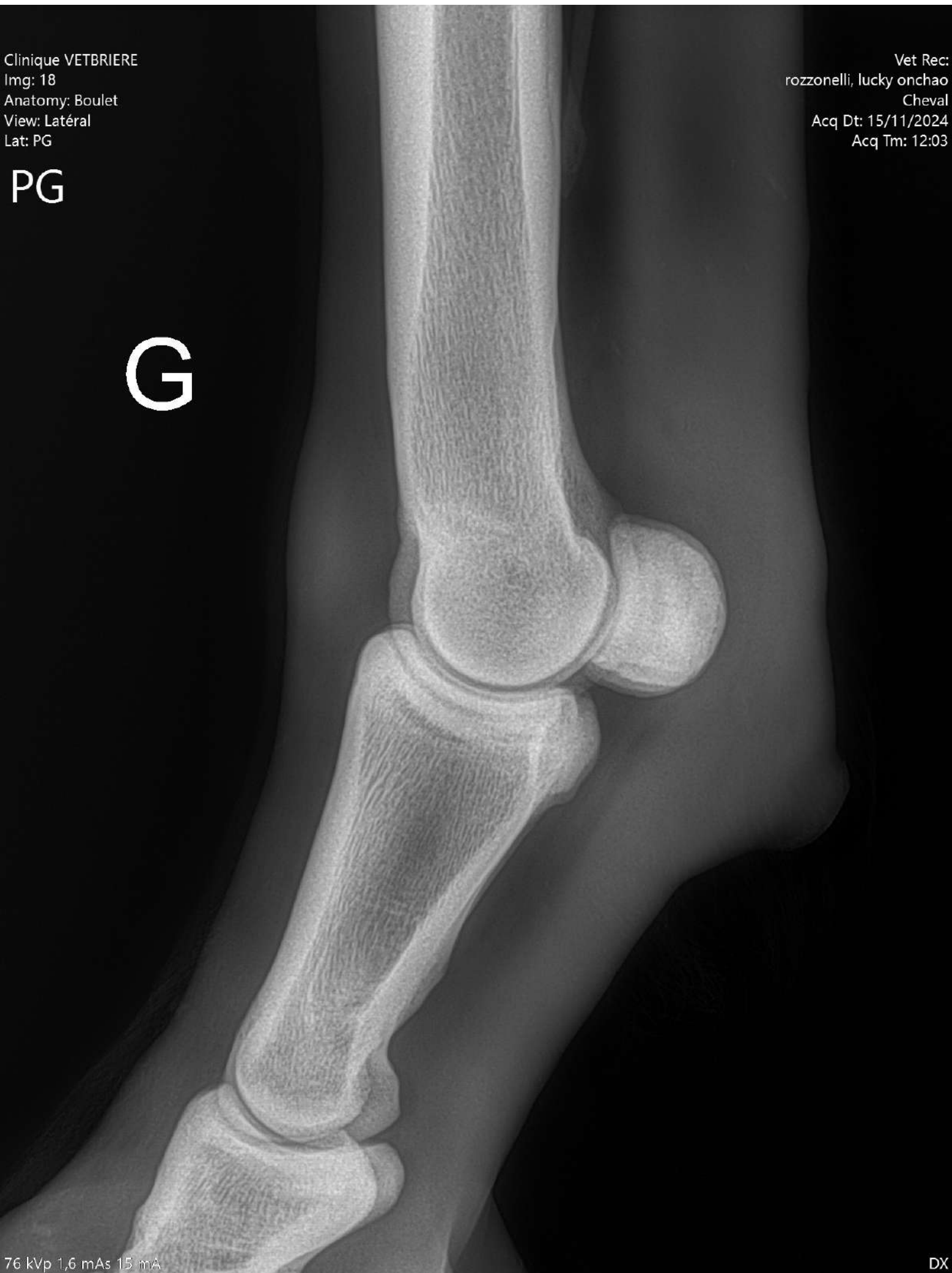


Clinique VETBRIERE
Img: 18
Anatomy: Boulet
View: Latéral
Lat: PG

Vet Rec:
rozzonelli, lucky onchao
Cheval
Acq Dt: 15/11/2024
Acq Tm: 12:03

PG

G



Clinique VETBRIERE
Img: 20
Anatomy: Grasset
View: Latéral
Lat: PG

Vet Rec
razzonelli, lucky oncha
Cheswal
Acq. Dt: 15/11/2024
Acq. Time: 12:04

G

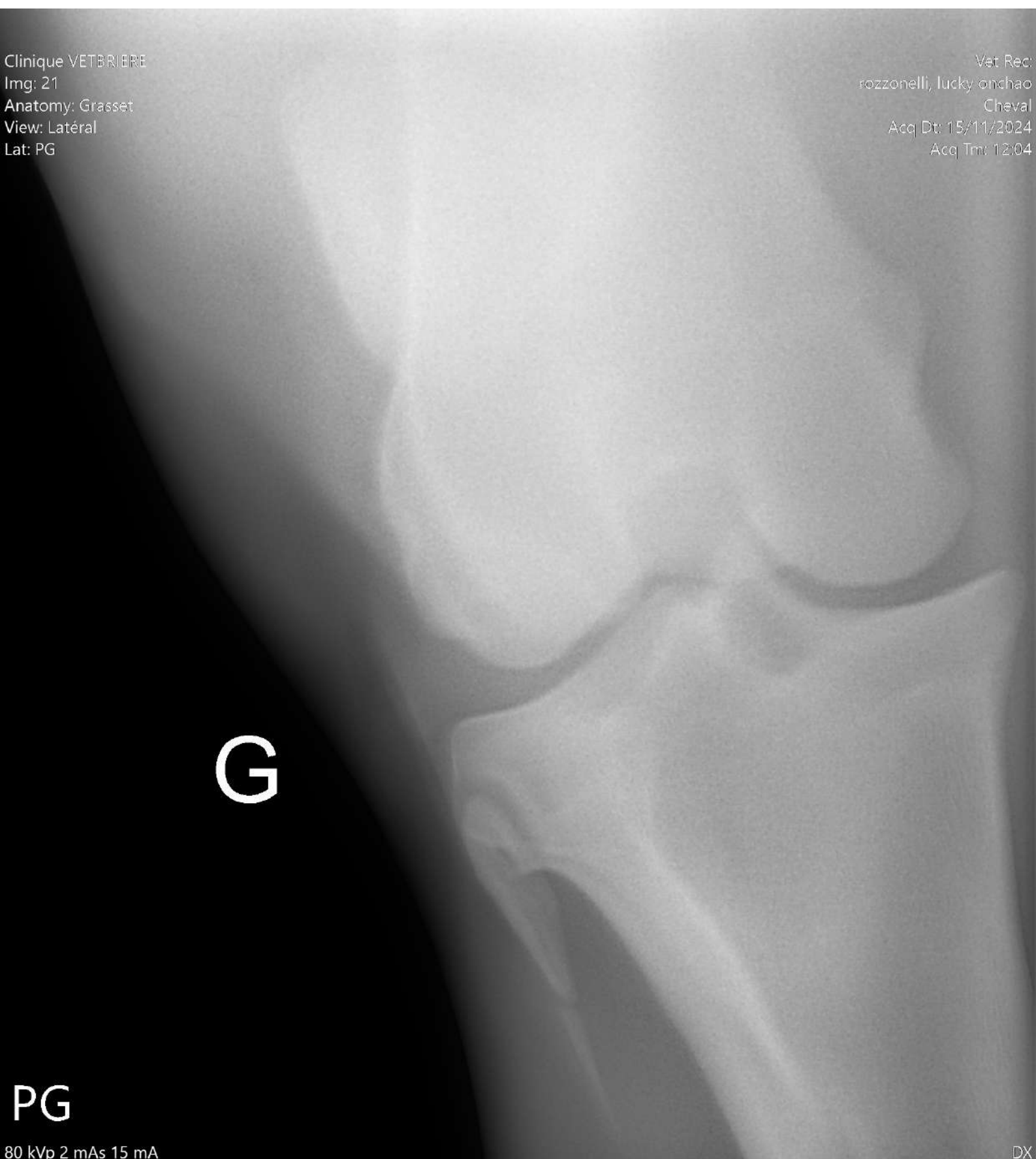
PG

80 kVp 2 mAs 15 mA

DX

Clinique VETBRIERE
Img: 21
Anatomy: Grasset
View: Latéral
Lat: PG

Vet Rec:
rozzonelli, lucky onchao
Cheval
Acq Dt: 15/11/2024
Acq Tm: 12:04



G

PG

80 kVp 2 mAs 15 mA

DX