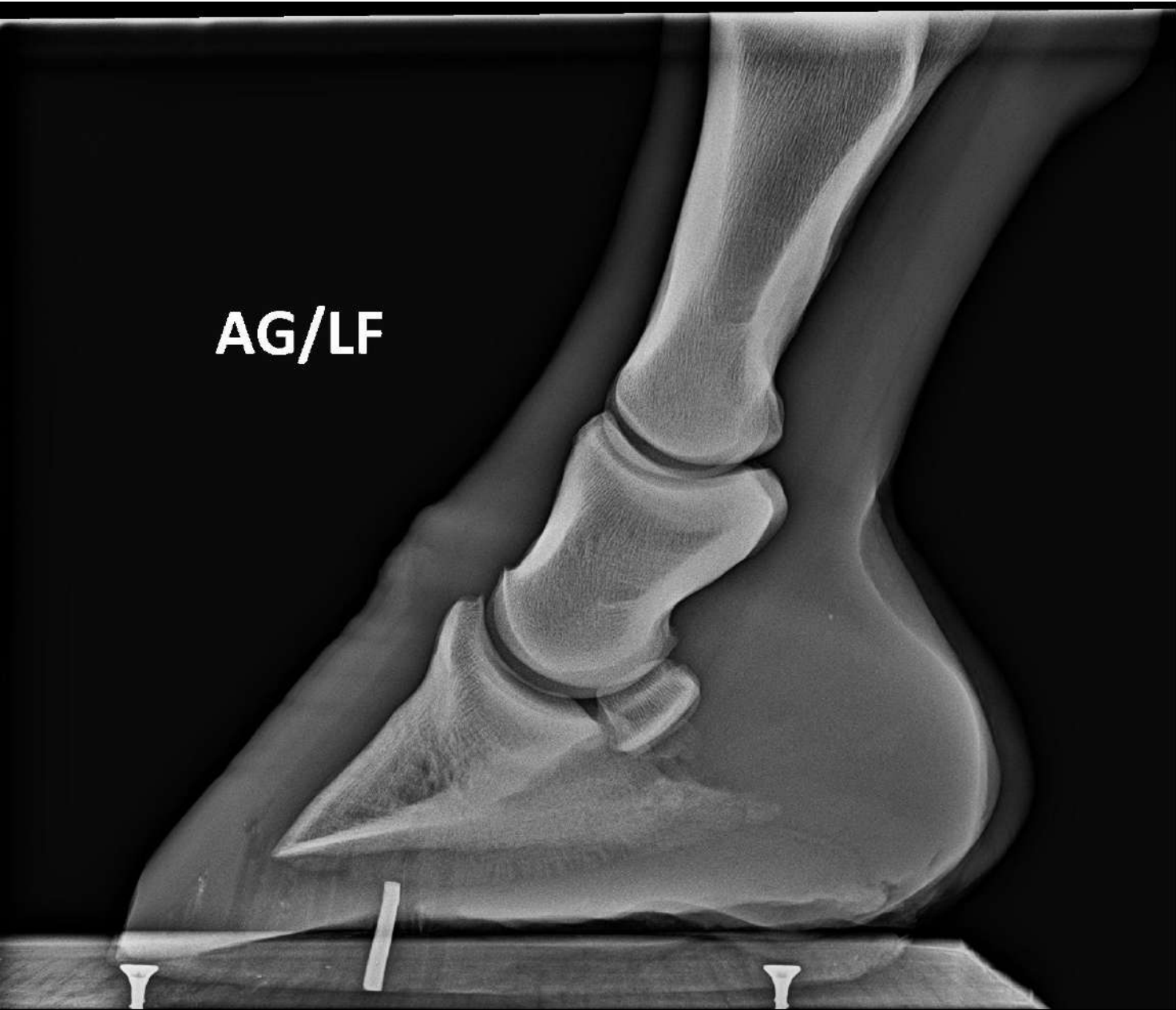


AG/LF

JINGLE DE RIVERLAND  
RIVERLAND

11/15/2024  
SELARL EQUISYN

AG/LF



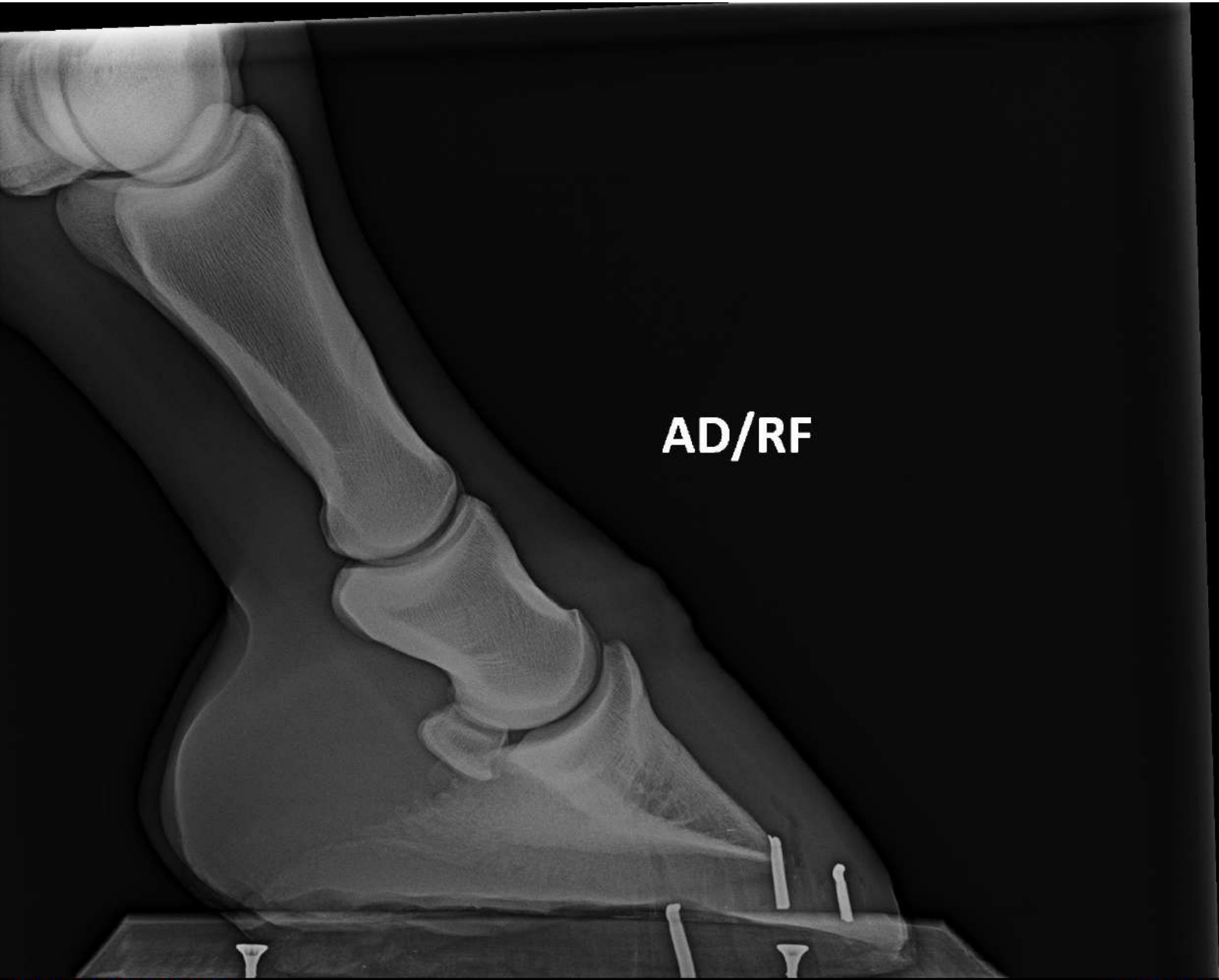
JINGLE DE RIVERLAND  
RIVERLAND

11/15/2024  
SELARL EQUISYN

AD/RF

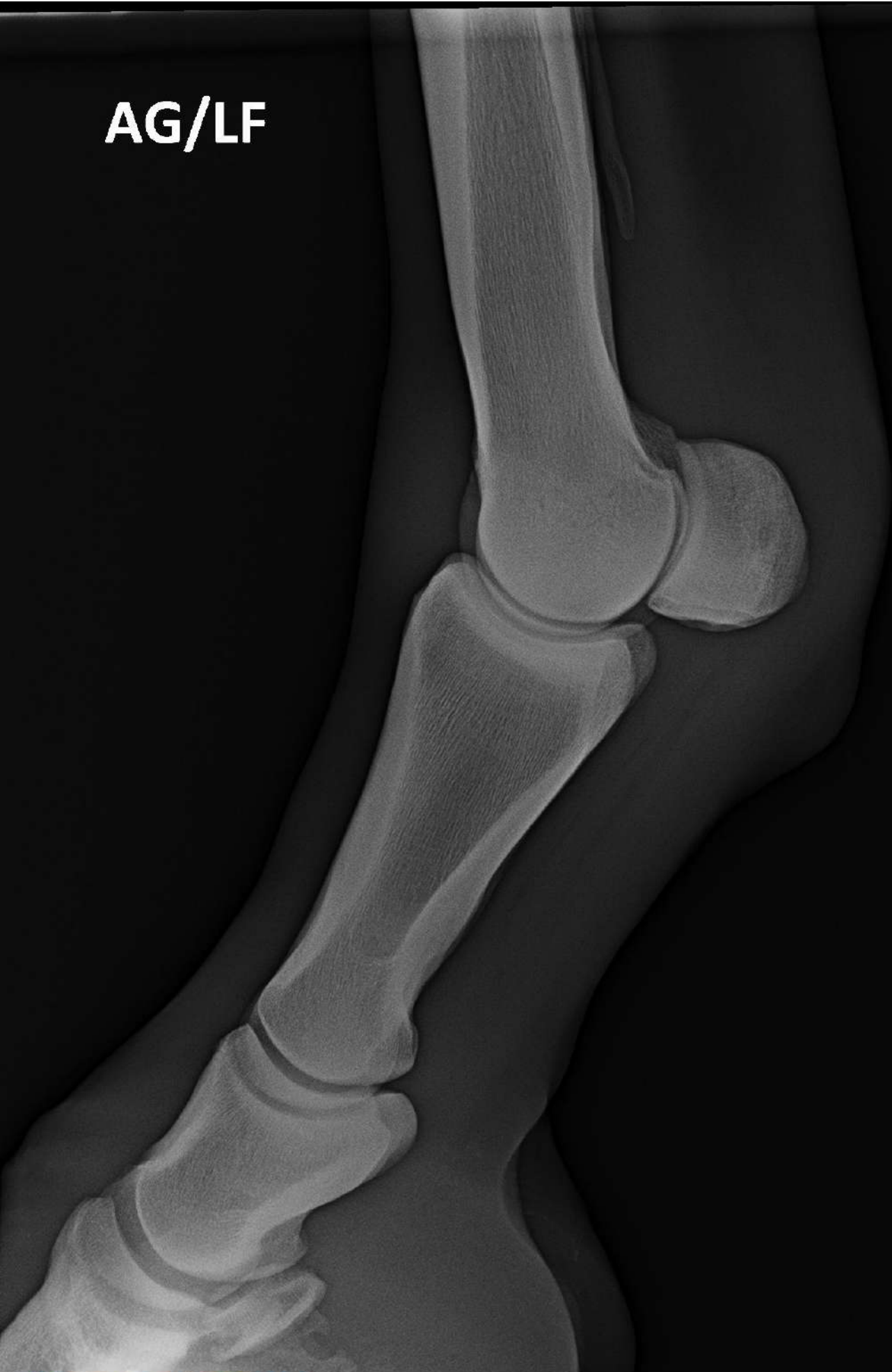JINGLE DE RIVERLAND  
RIVERLAND

11/15/2024  
SELARL EQUISYN



AD/RF

AG/LF





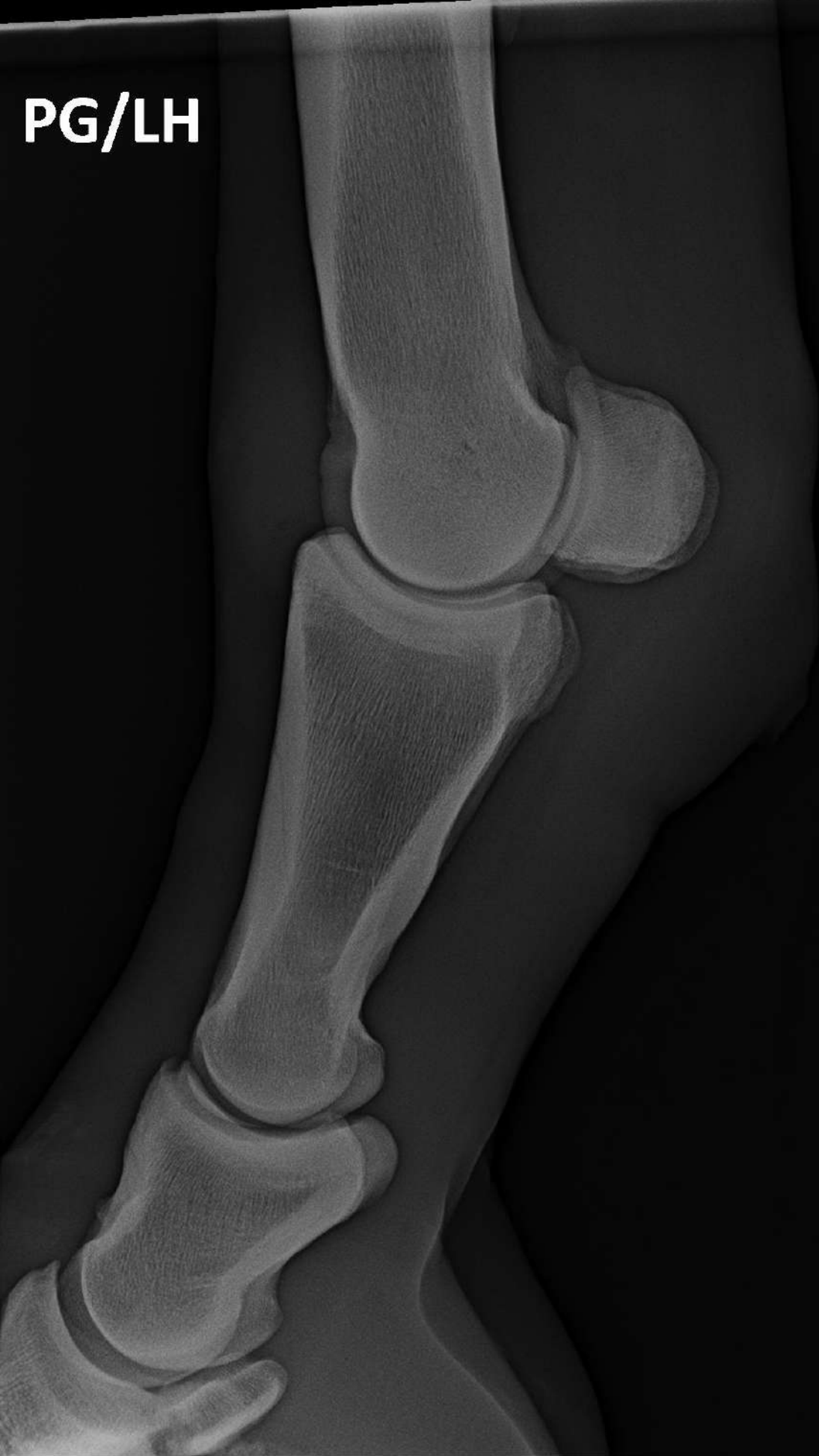An anteroposterior (AP) radiograph of a horse's knee joint. The image shows the distal femur at the top, the patella in the middle, and the proximal tibia at the bottom. The joint space is visible between the bones. The text 'AG/LF' is printed in white in the upper right corner of the image.

**AG/LF**

JINGLE DE RIVERLAND  
RIVERLAND

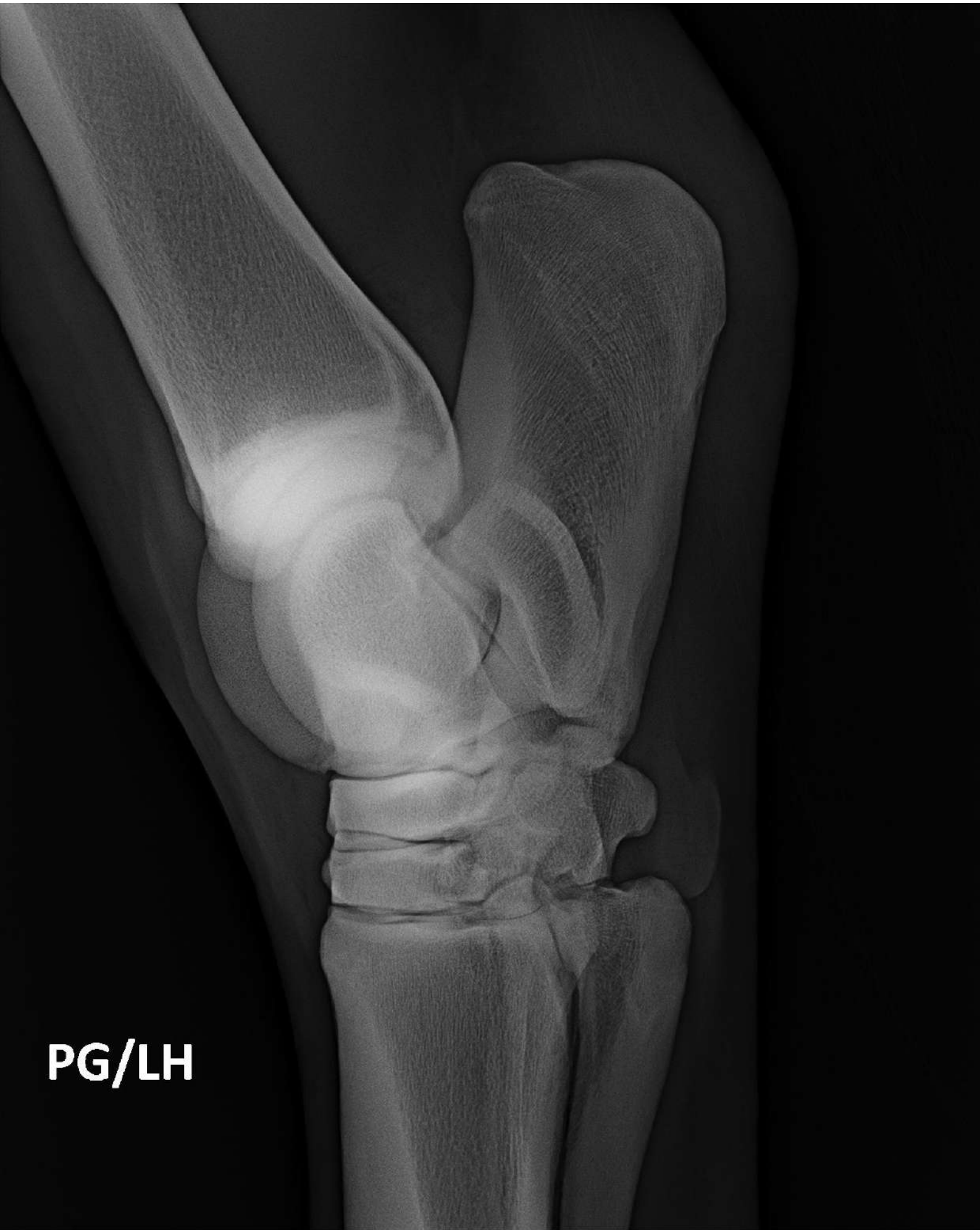11/15/2024  
SELARL EQUISYN

PG/LH



JINGLE DE RIVERLAND  
RIVERLAND

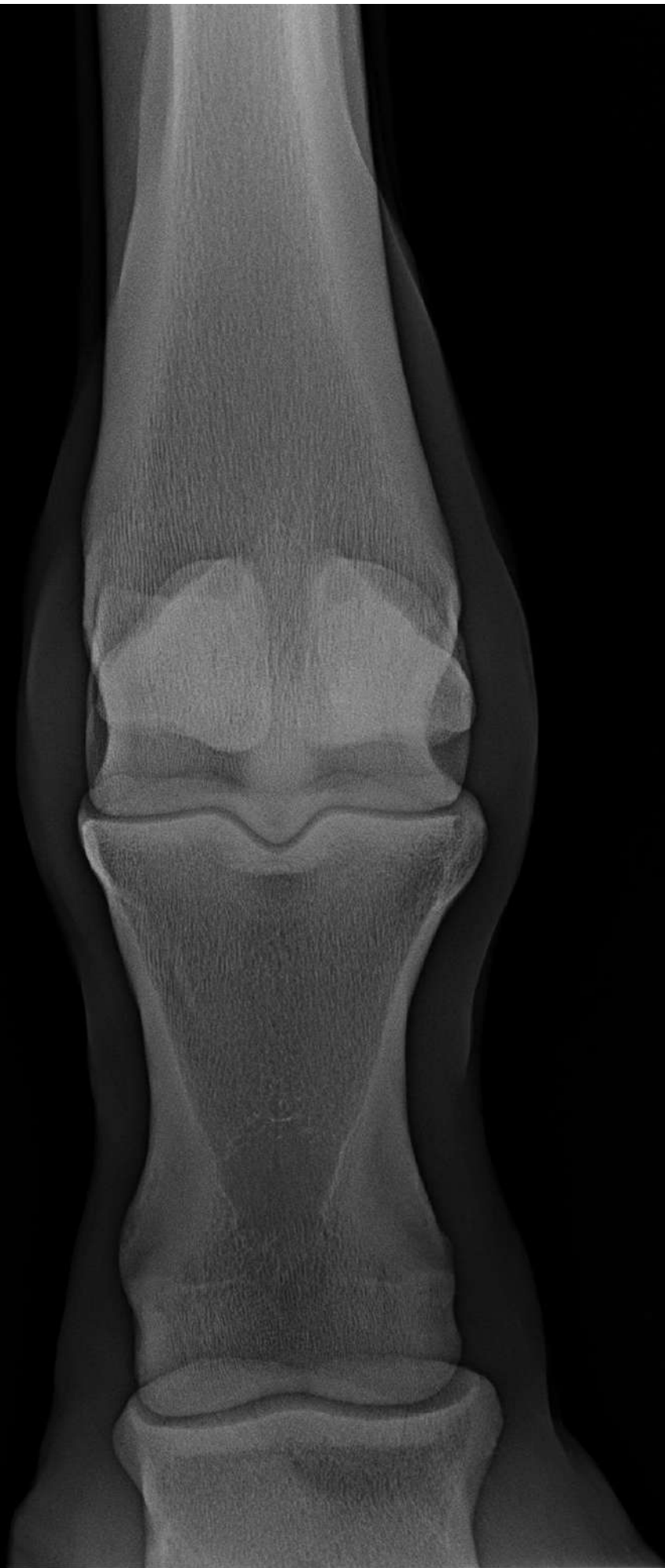11/15/2024  
SELARL EQUISYN



**PG/LH**

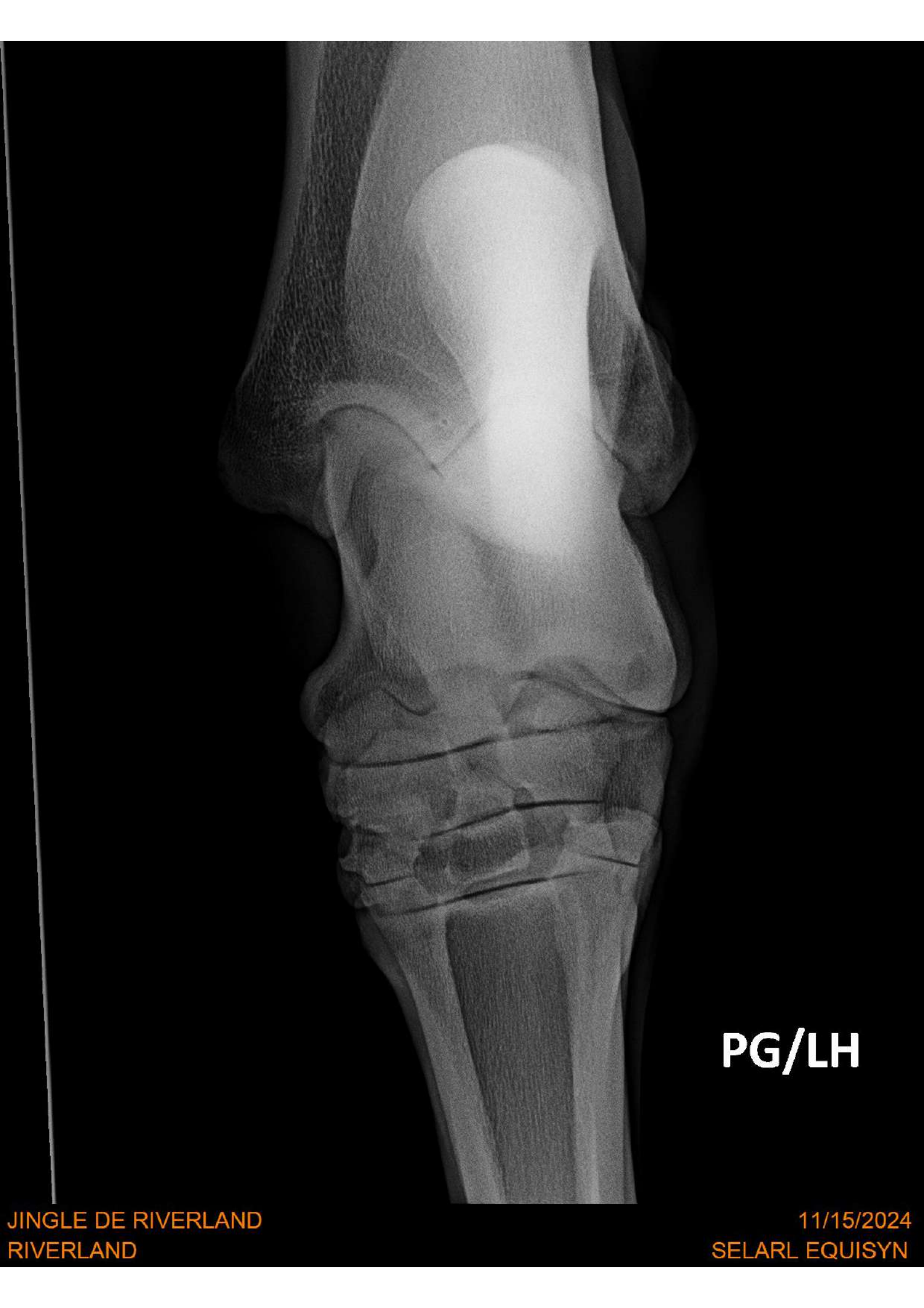

PG/LH



JINGLE DE RIVERLAND  
RIVERLAND

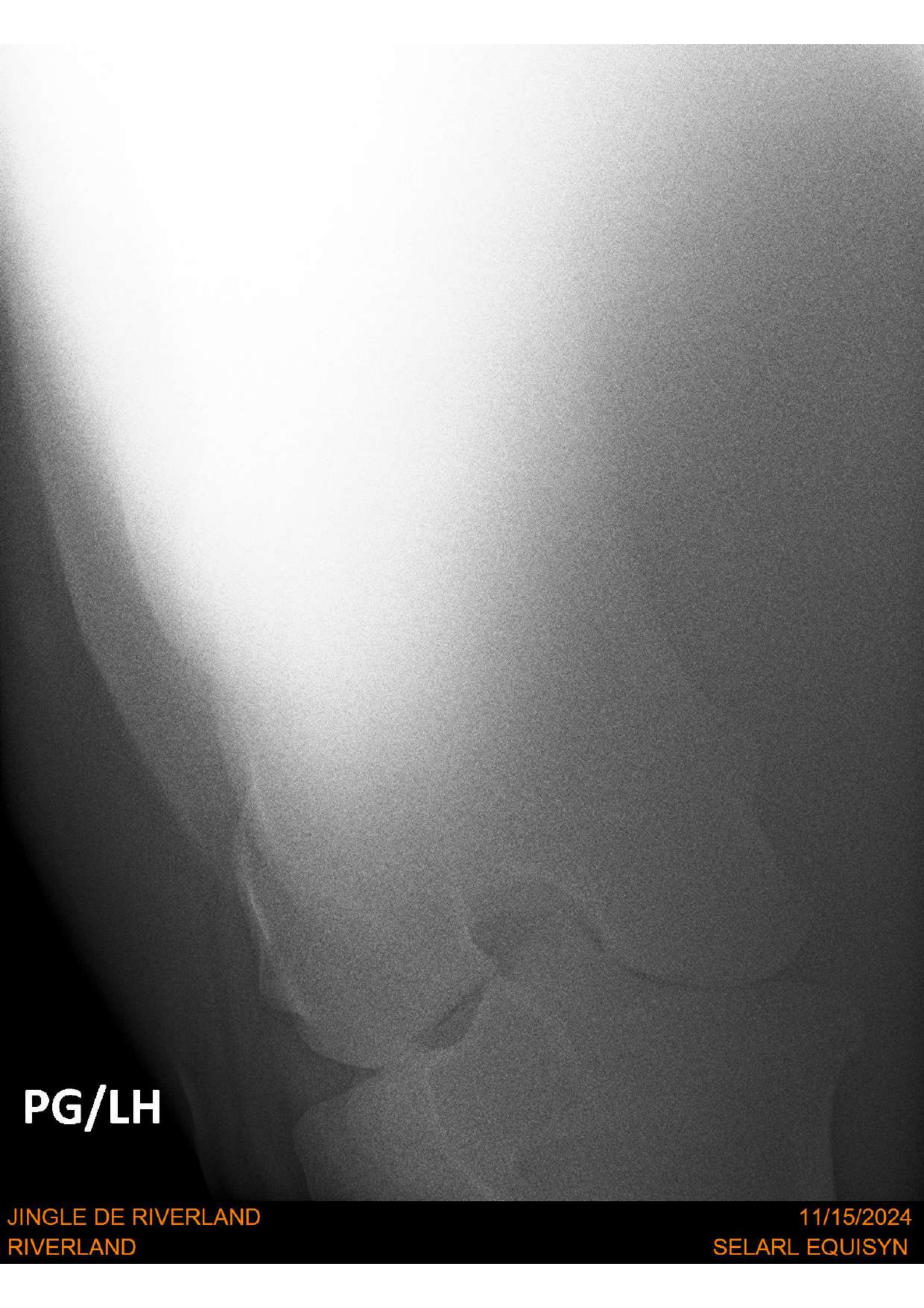
11/15/2024  
SELARL EQUISYN



**PG/LH**

PG/LH





**PG/LH**

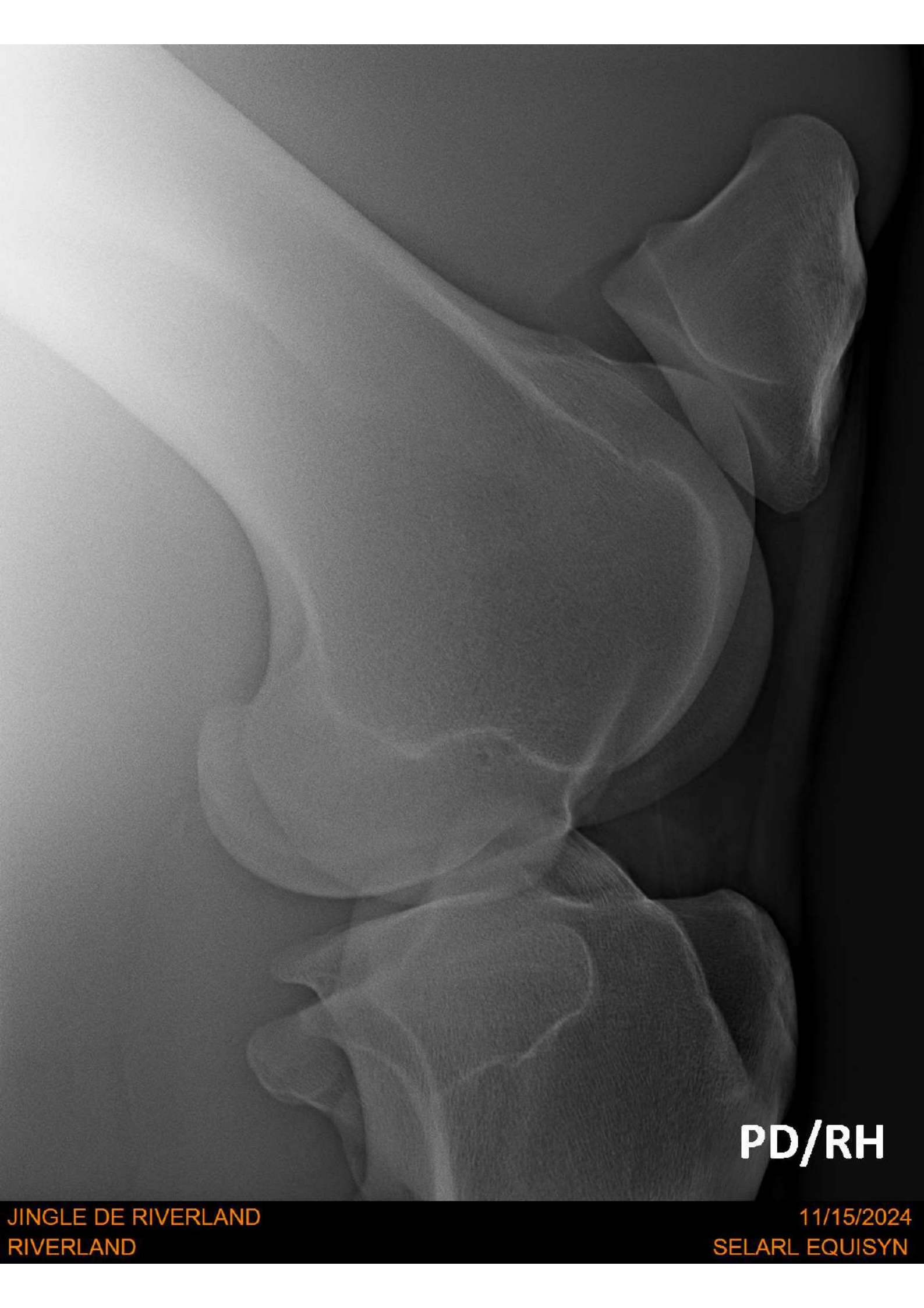JINGLE DE RIVERLAND  
RIVERLAND

11/15/2024  
SELARL EQUISYN



PD/RH

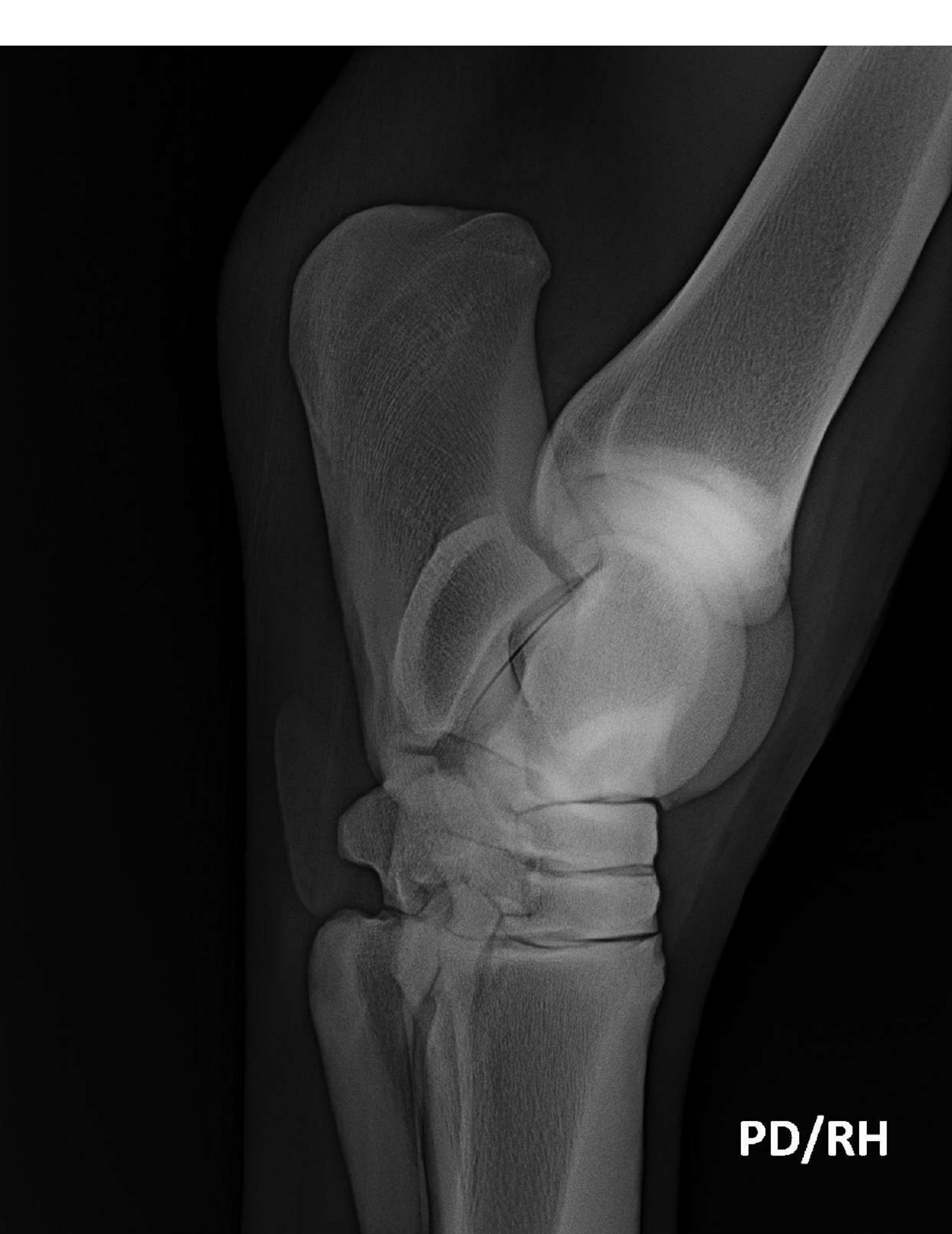



**PD/RH**

JINGLE DE RIVERLAND  
RIVERLAND

11/15/2024  
SELARL EQUISYN

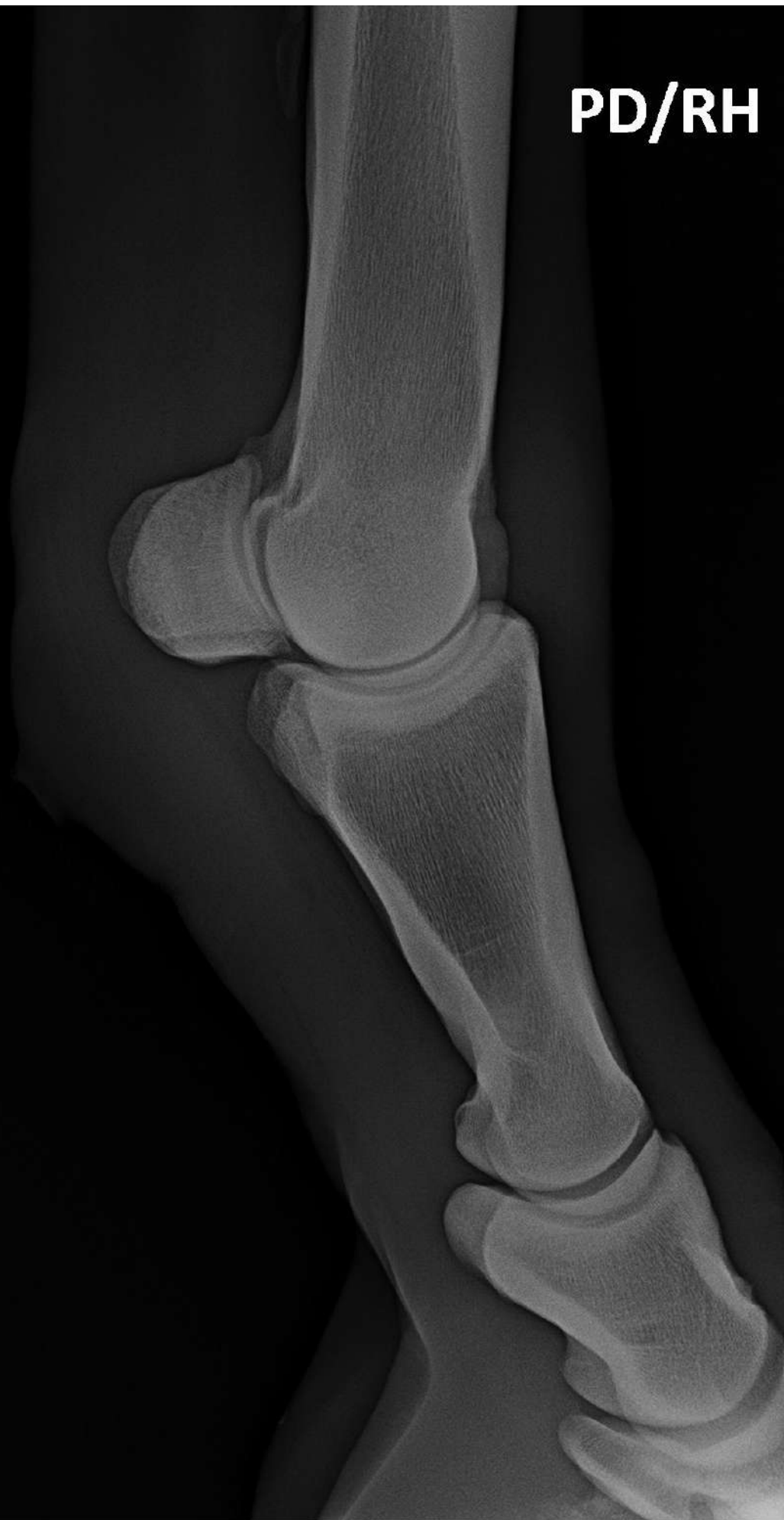

**PD/RH**

JINGLE DE RIVERLAND  
RIVERLAND

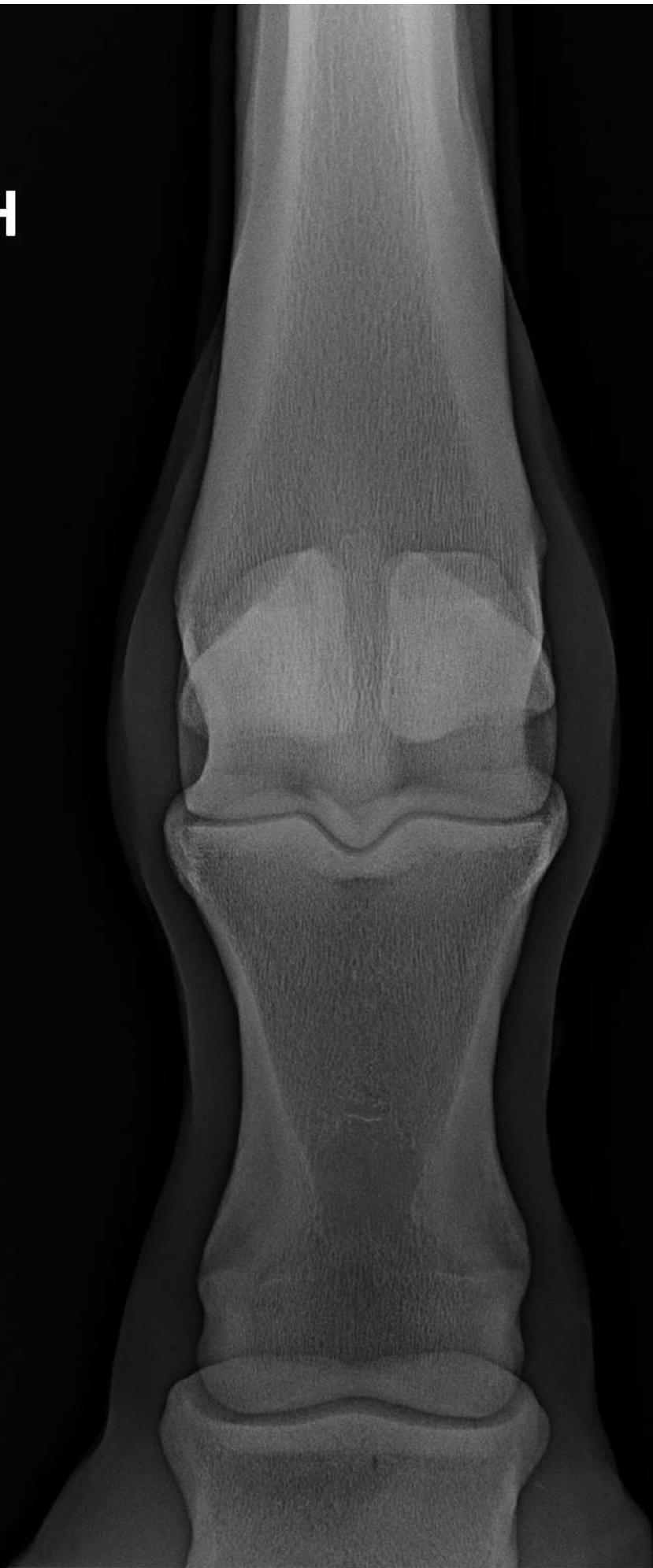11/15/2024  
SELARL EQUISYN

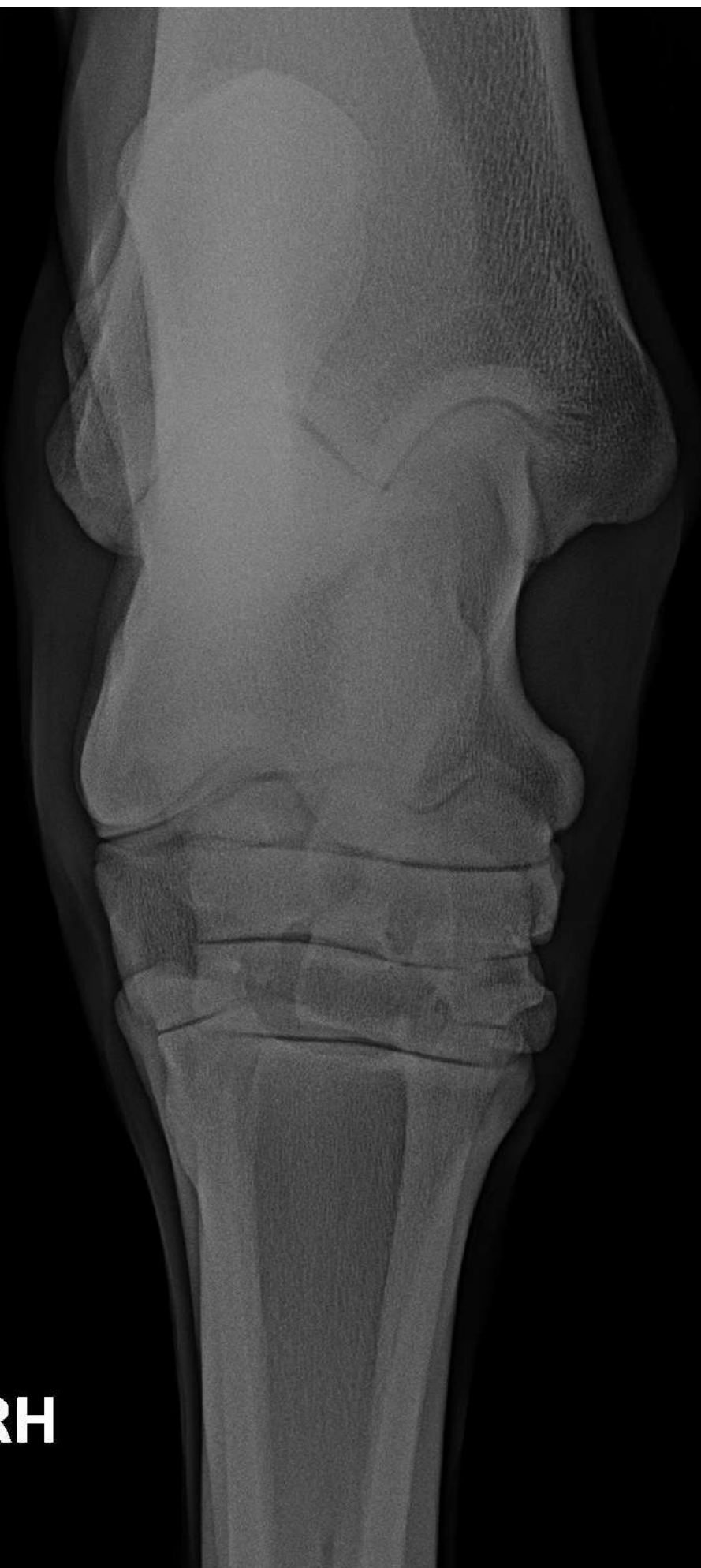PD/RH





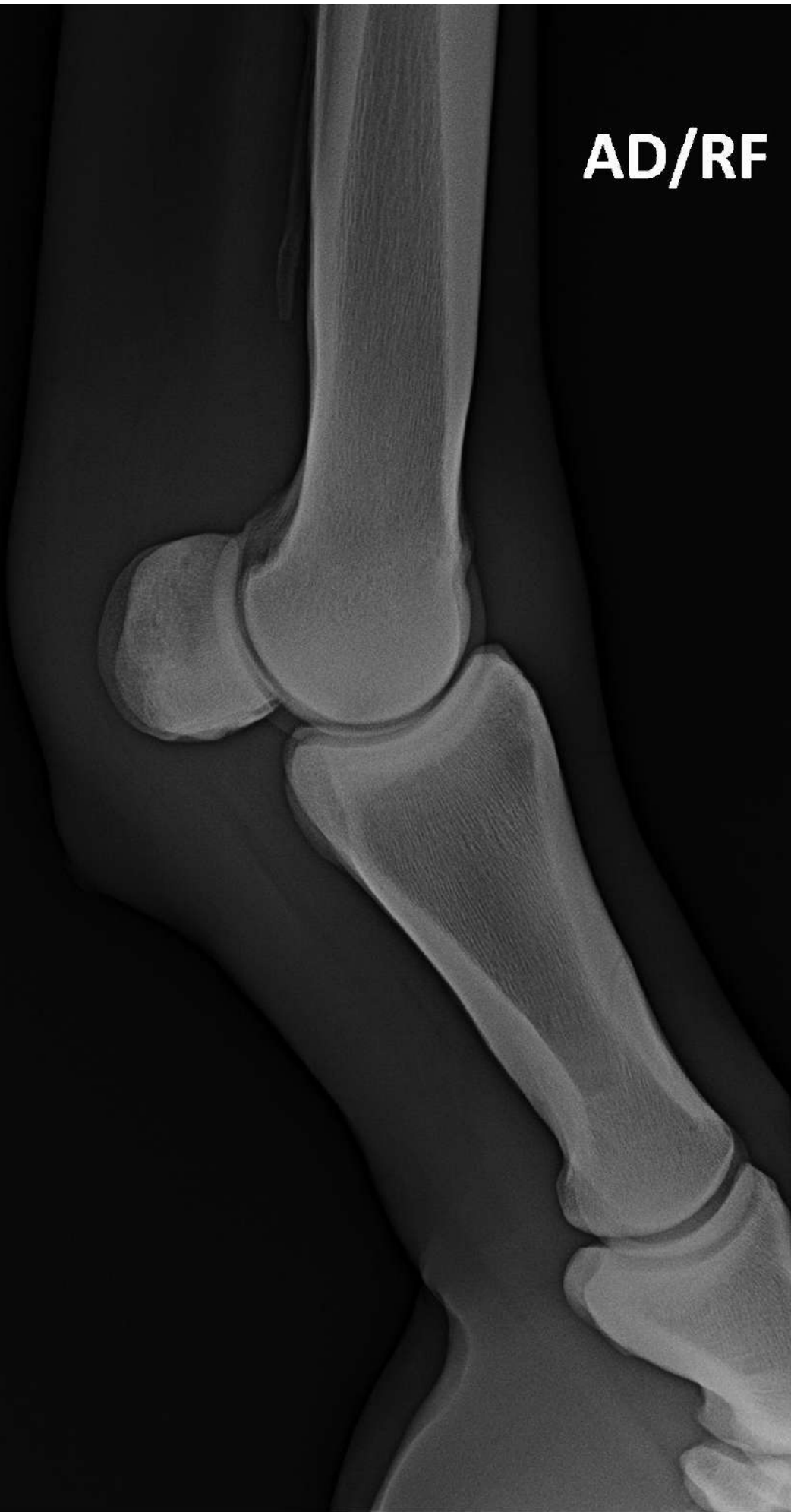PD/RH





**PD/RH**

**AD/RF**



**AD/RF**